

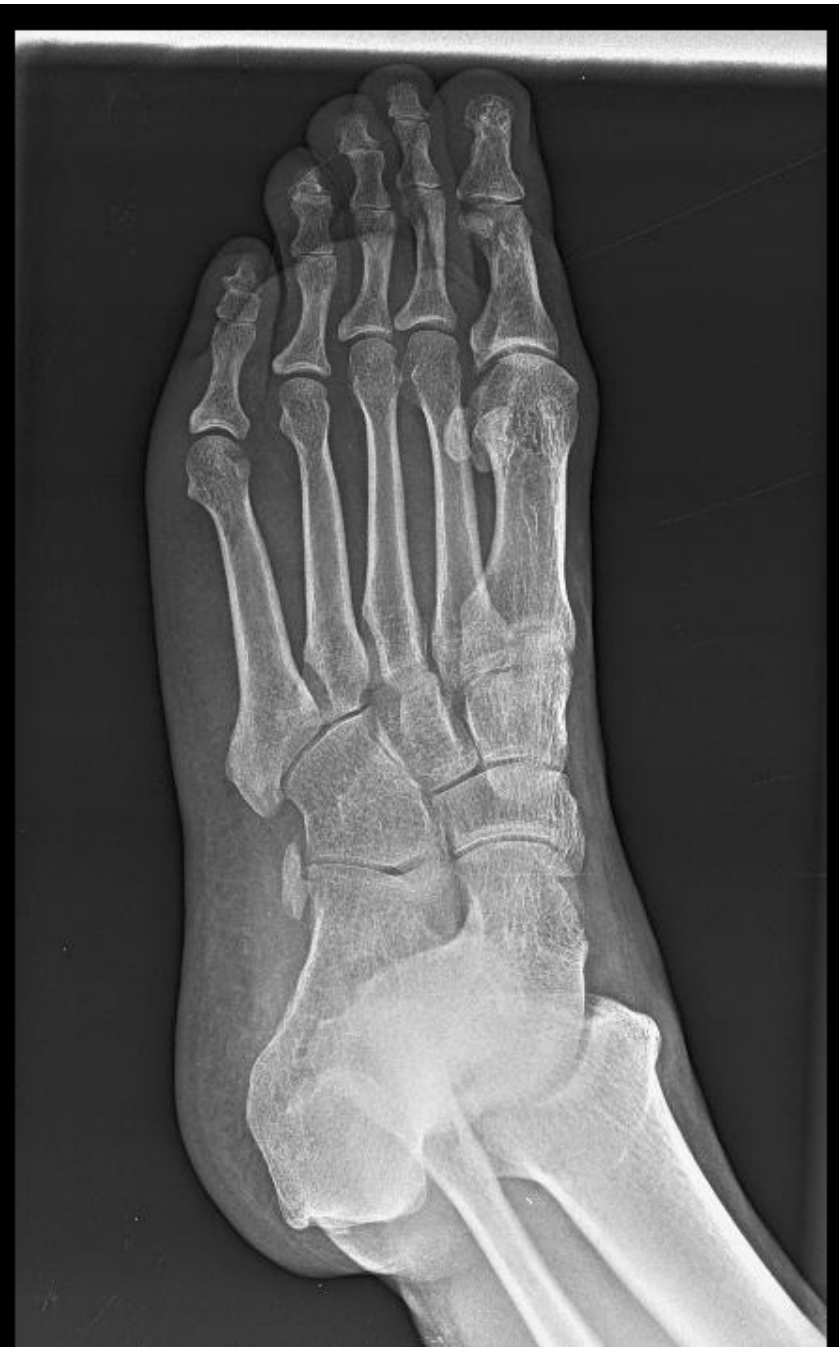
MICOD – 22.12.2023
Case contributor – Dr. Vikas Batra

MI-COD

MSS INDIA- Case Of the Day

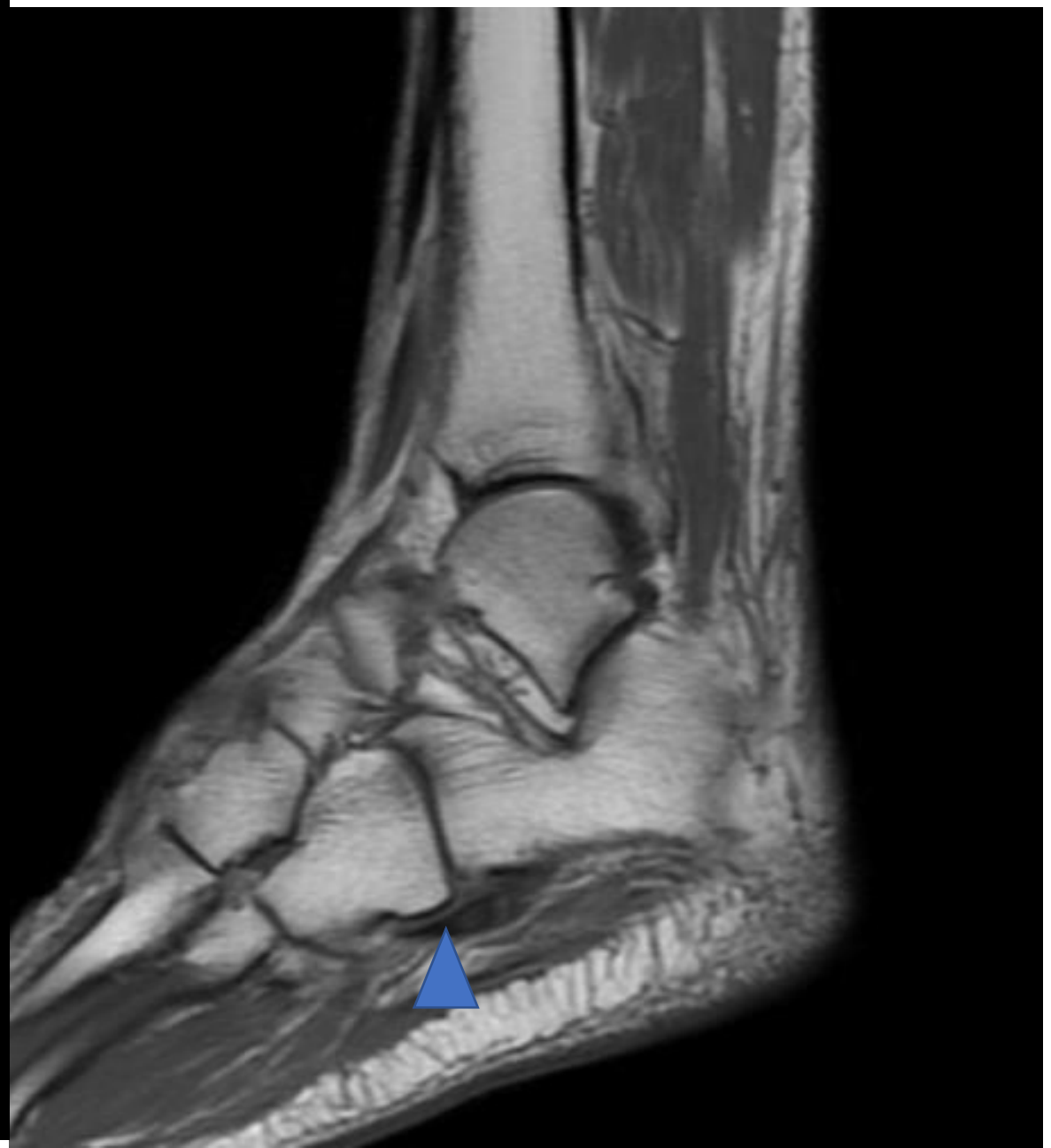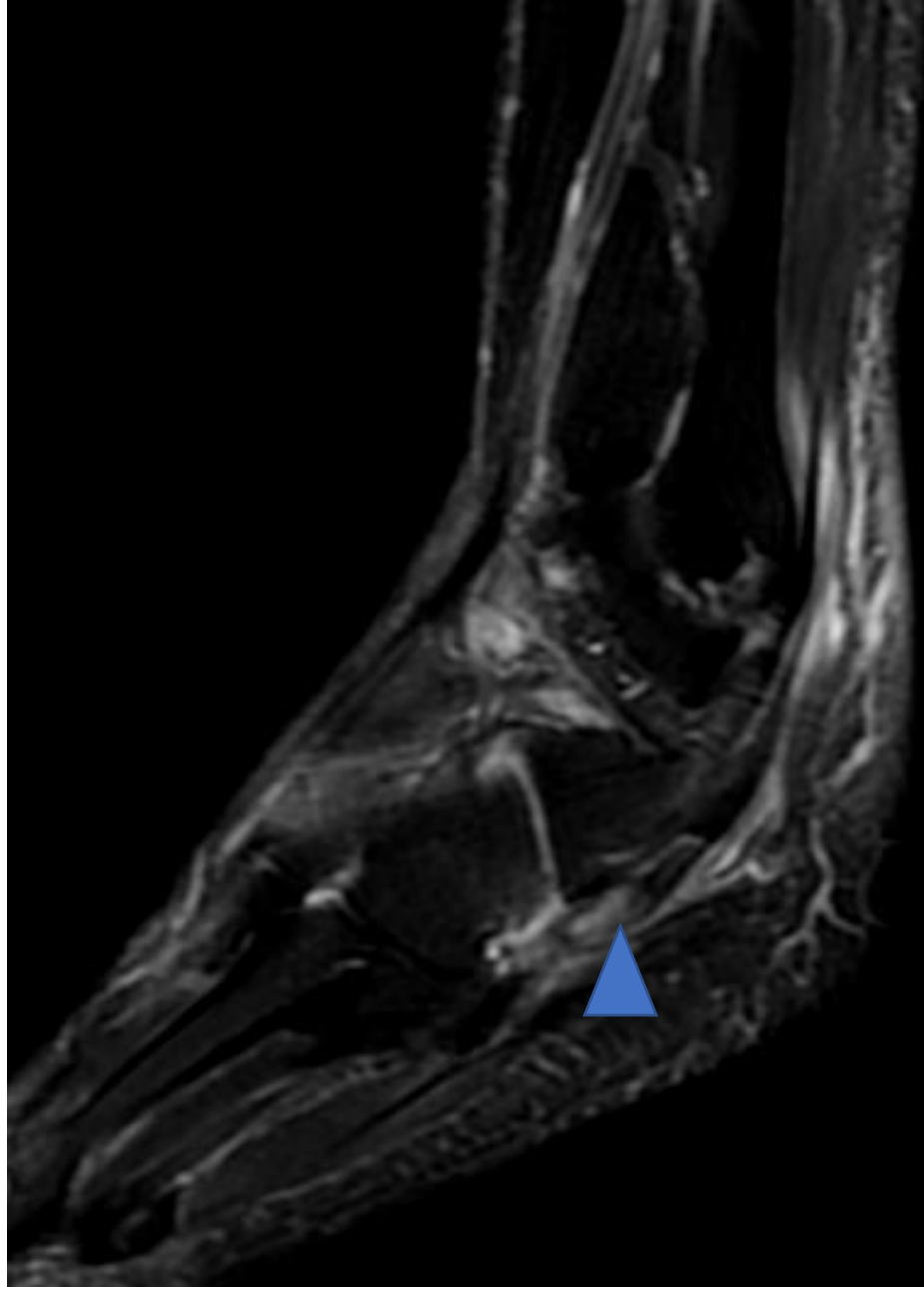


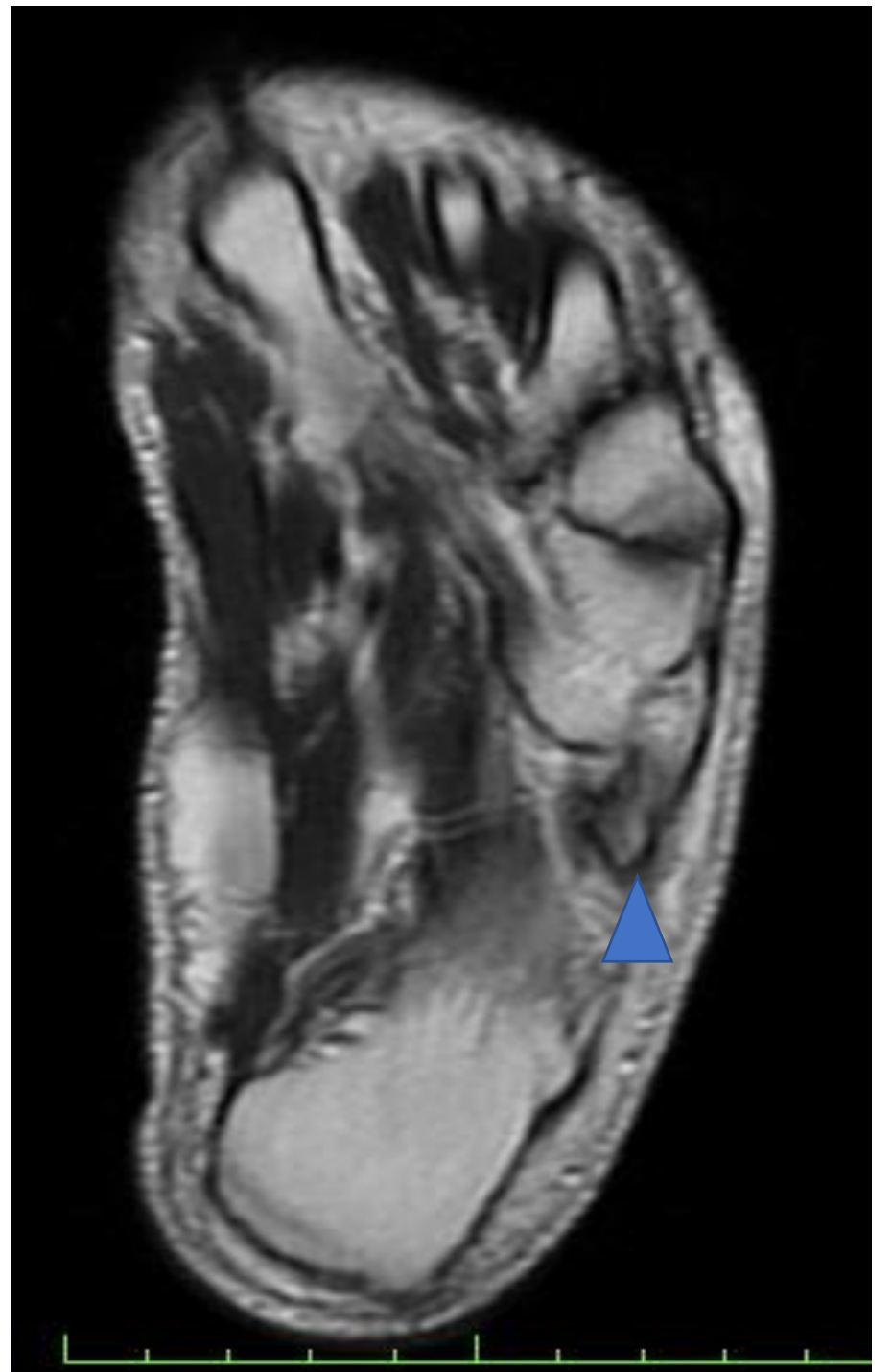
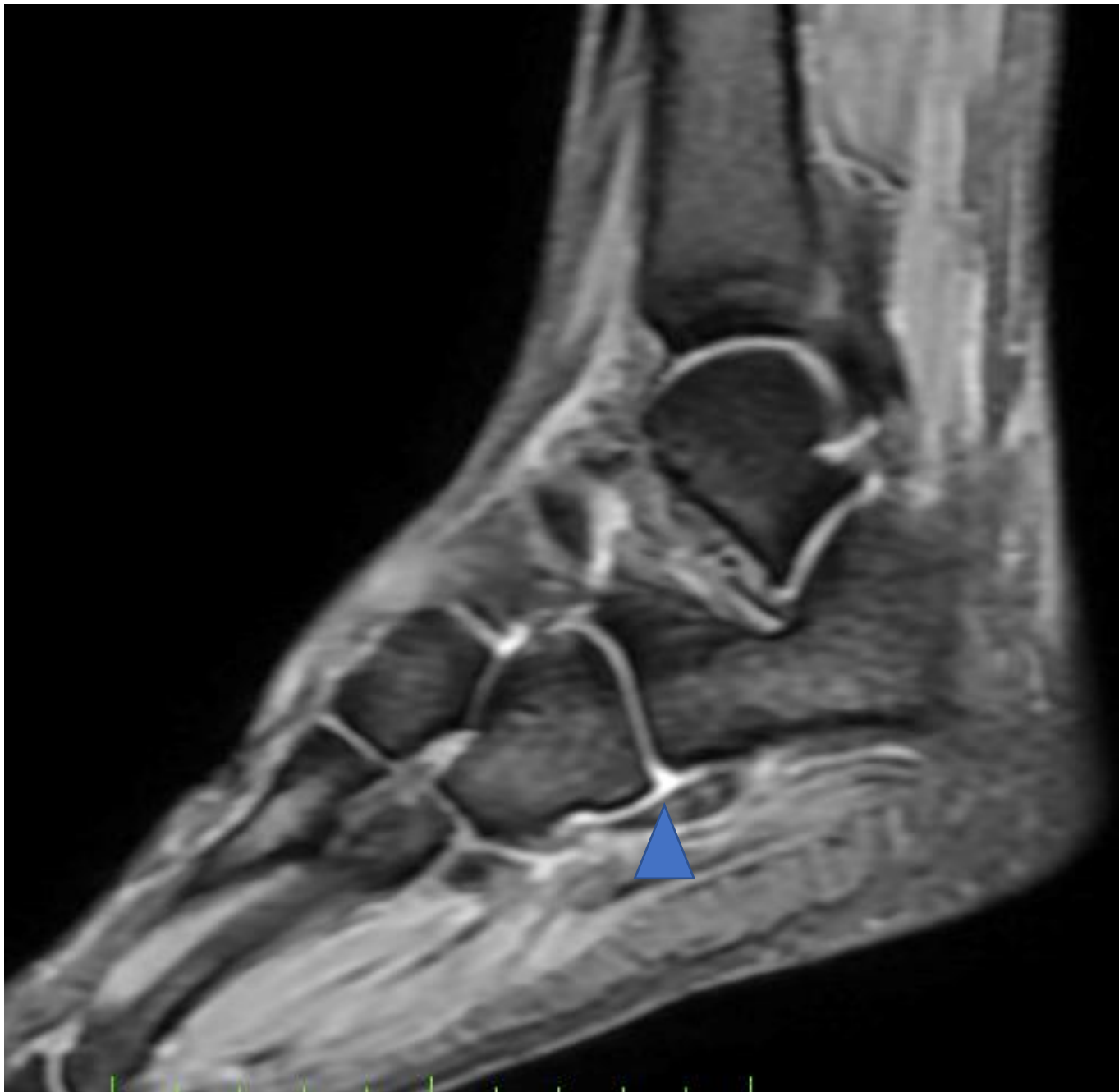A 40 years old male patient presenting with c/o pain in lateral aspect of right foot for past 3-4 months. No obvious history of trauma.

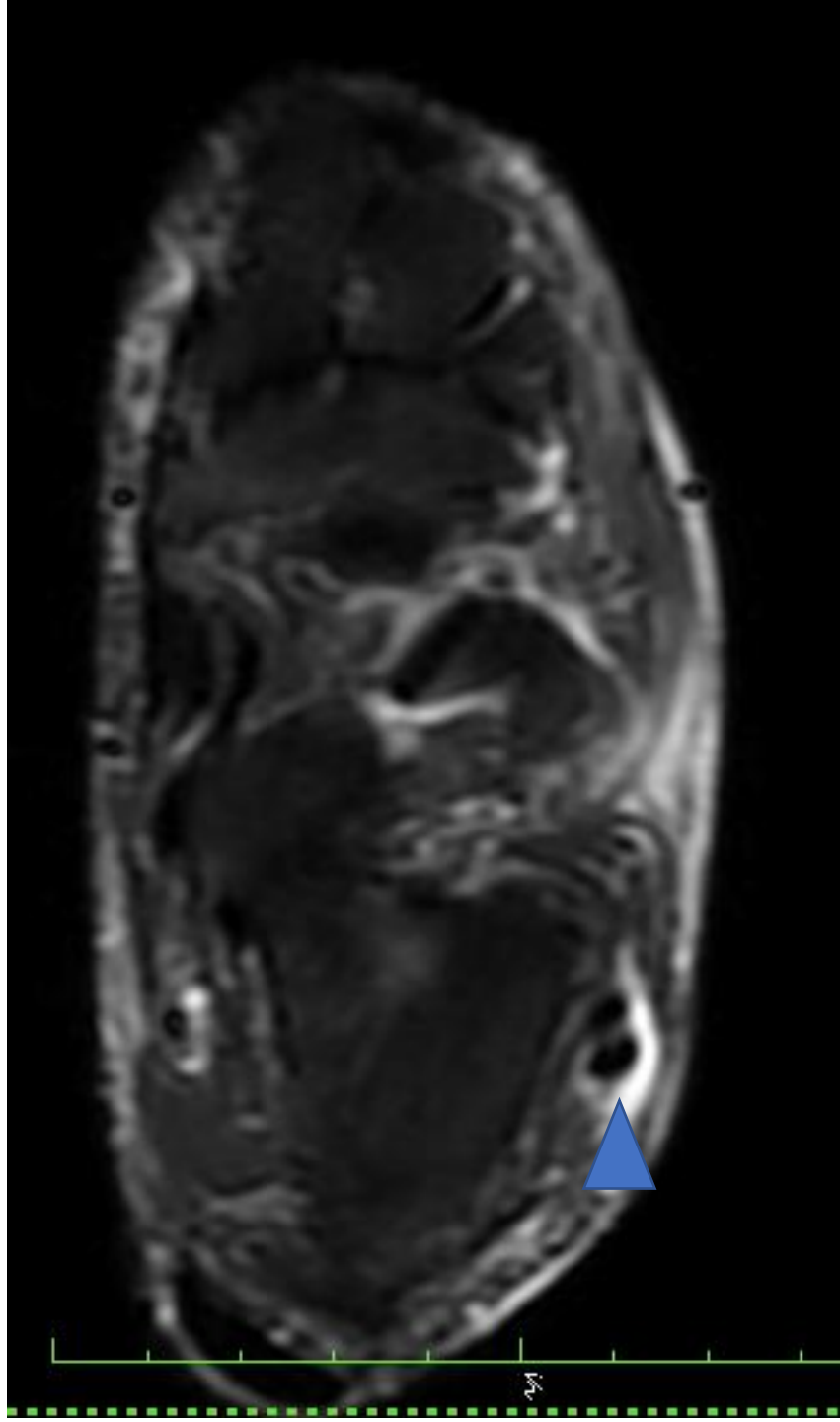


AP oblique radiograph of right foot.

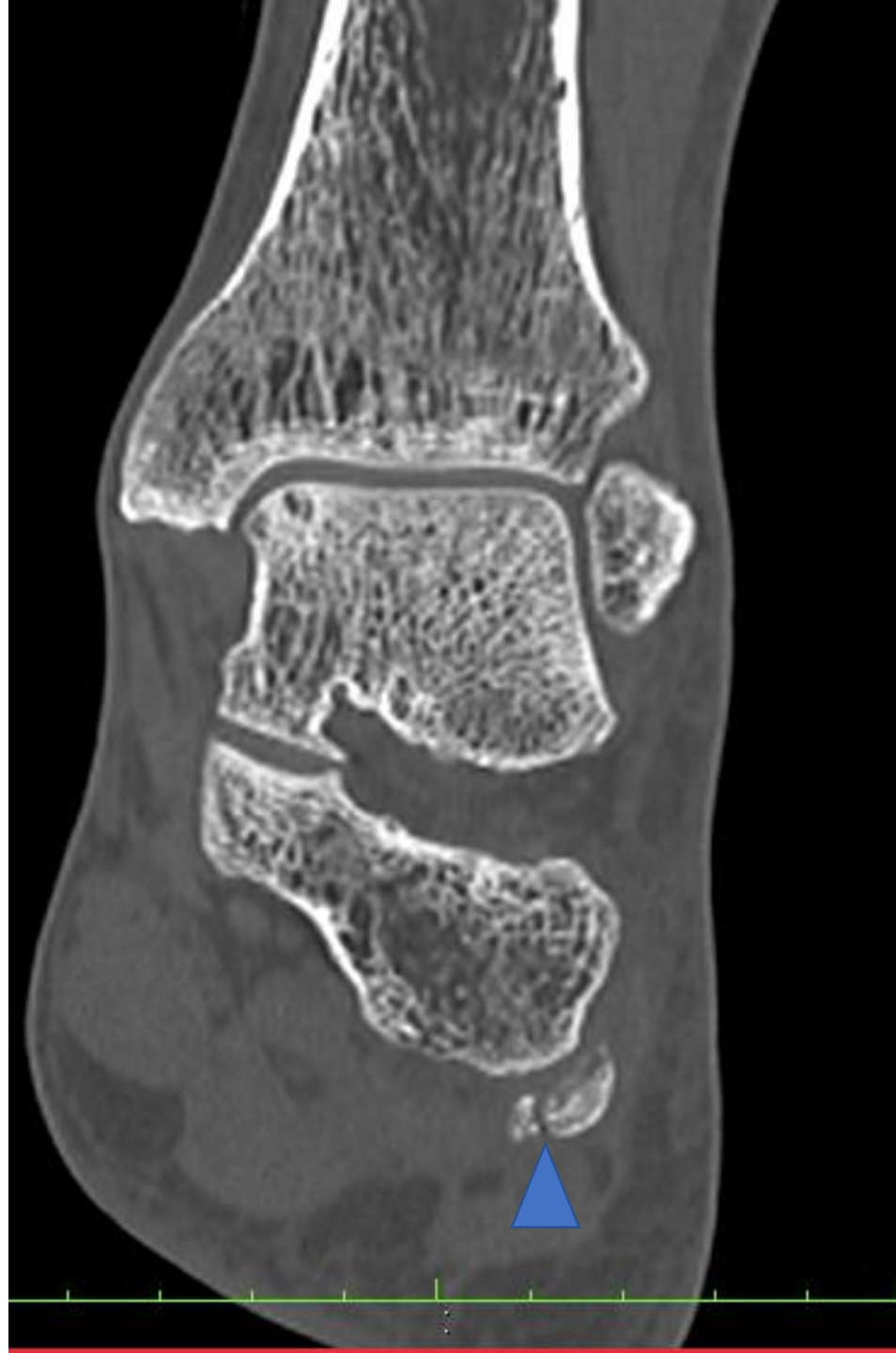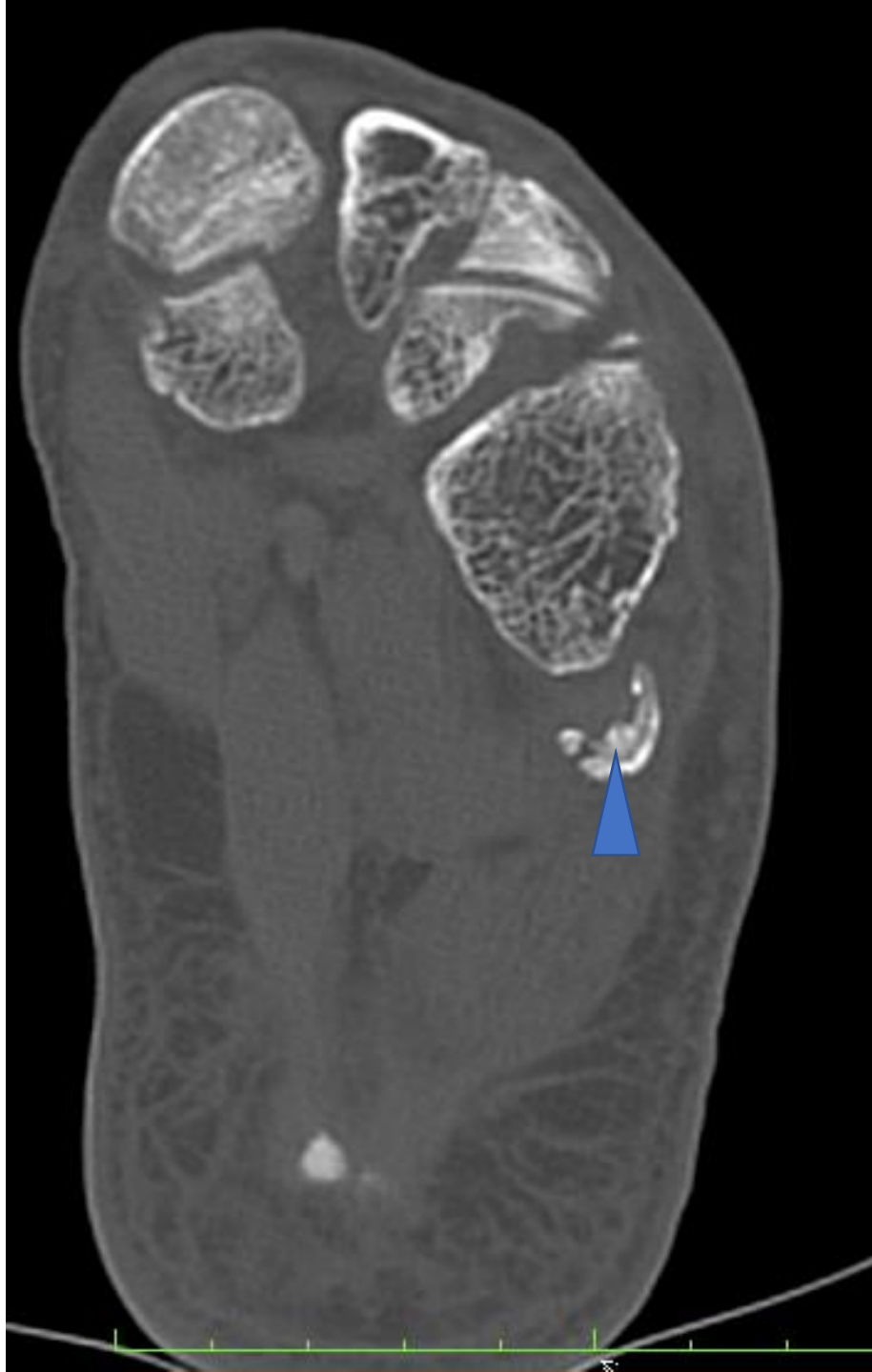- MR was advised.







- Radiograph of foot revealed elongated os peroneum appearing slightly sclerotic with respect to rest of the visualized bones.
- MRI revealed os peroneum within the tendon of peroneus longus with surrounding soft tissue edema and peroneal tenosynovitis. S/o Os peroneum syndrome.



- CT revealed fragmentation/ bipartite and mild sclerosis of os peroneum s/o os peroneum syndrome.