

MICOD – 21/12/2023

Case contributor – Dr. Harun Gupta (MSK Teaching Room)

MI-COD

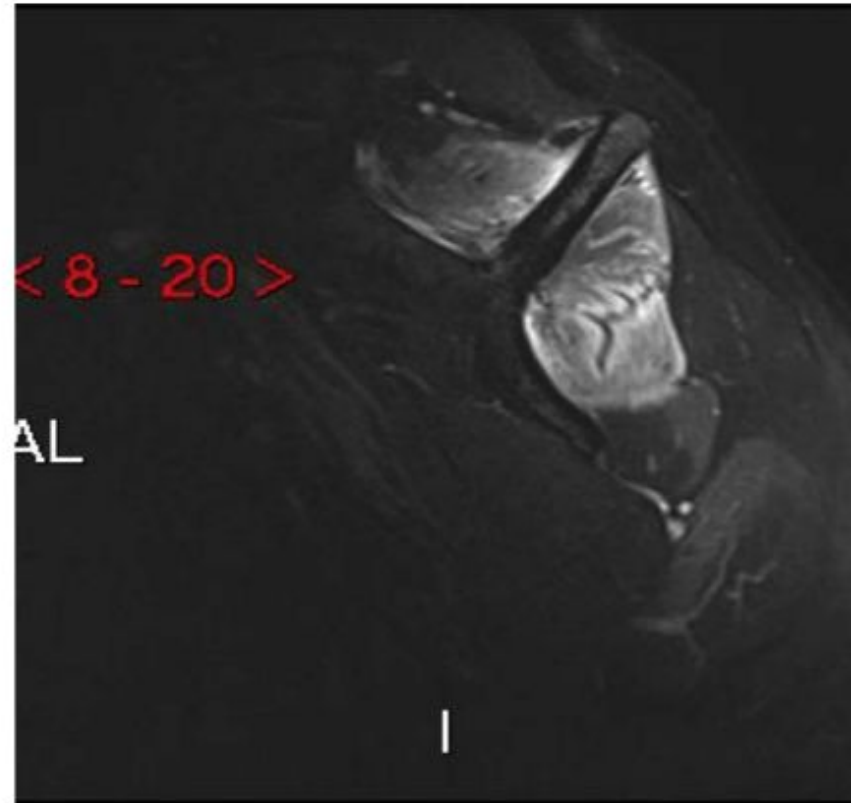
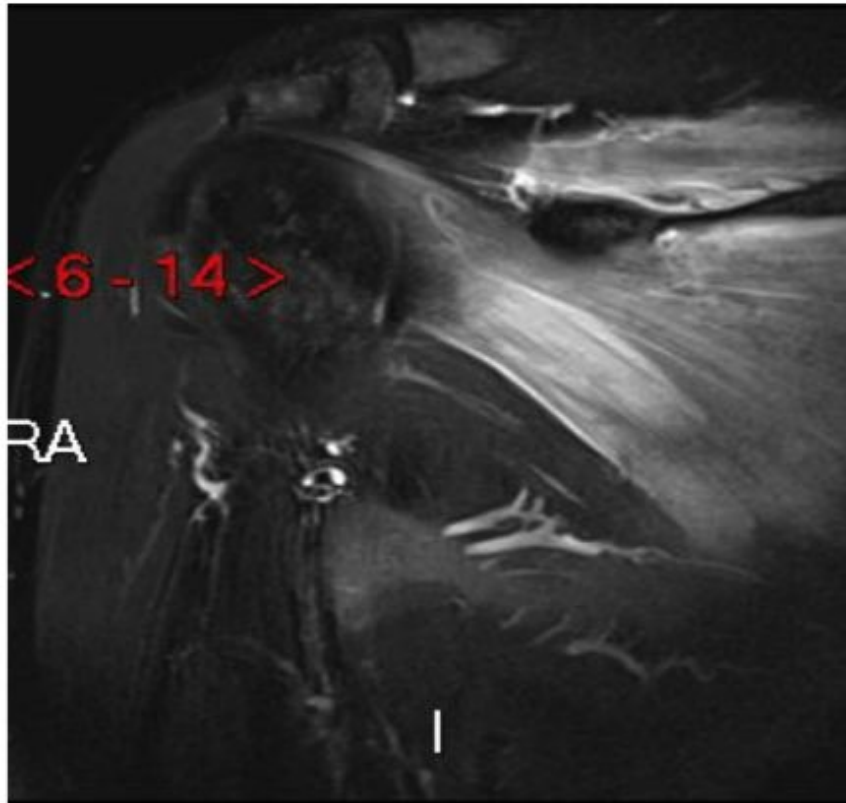
MSS INDIA- Case Of the Day



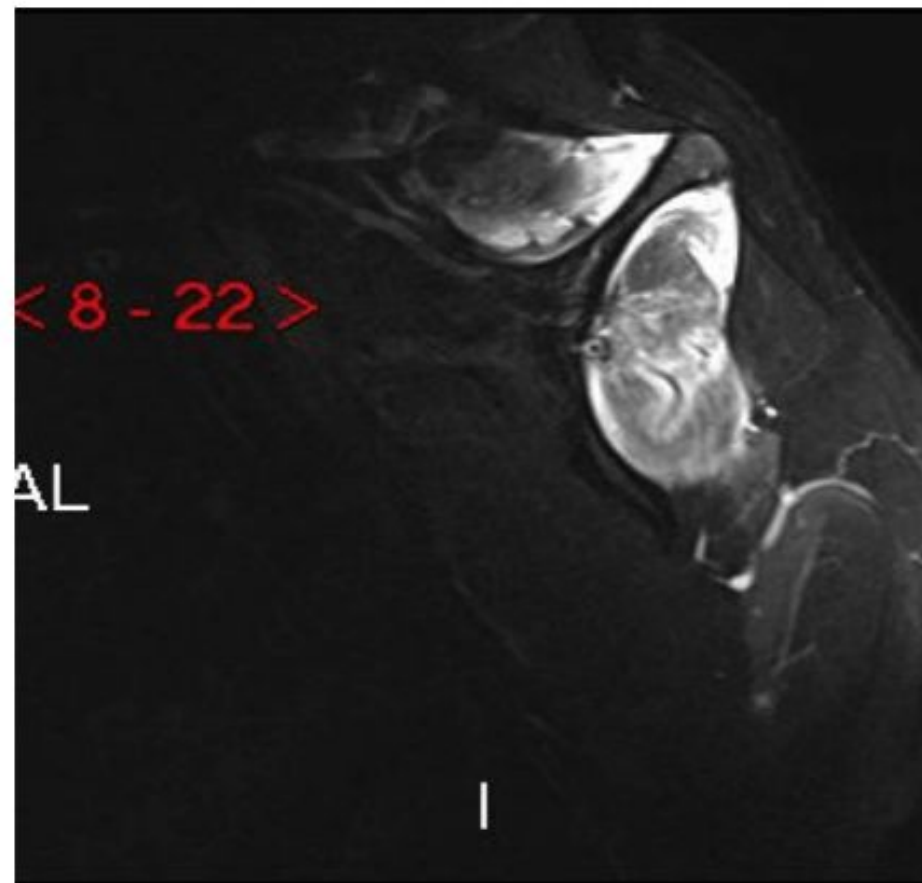
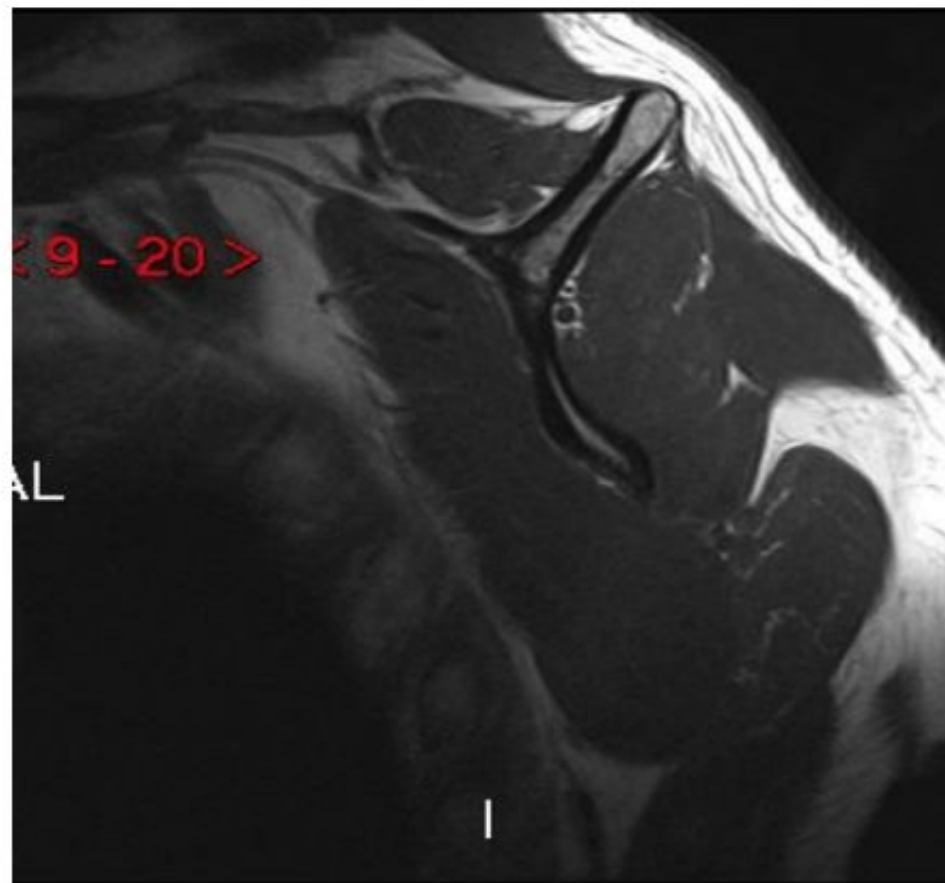
Case 1

h/o shoulder weakness

Case 1



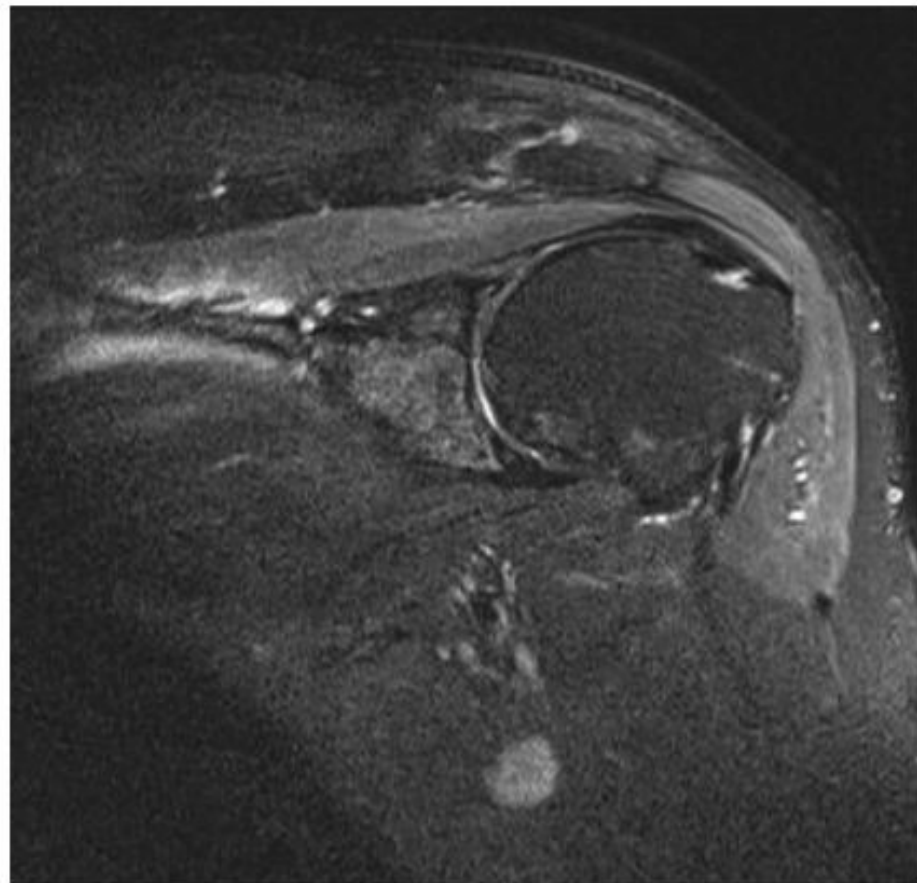
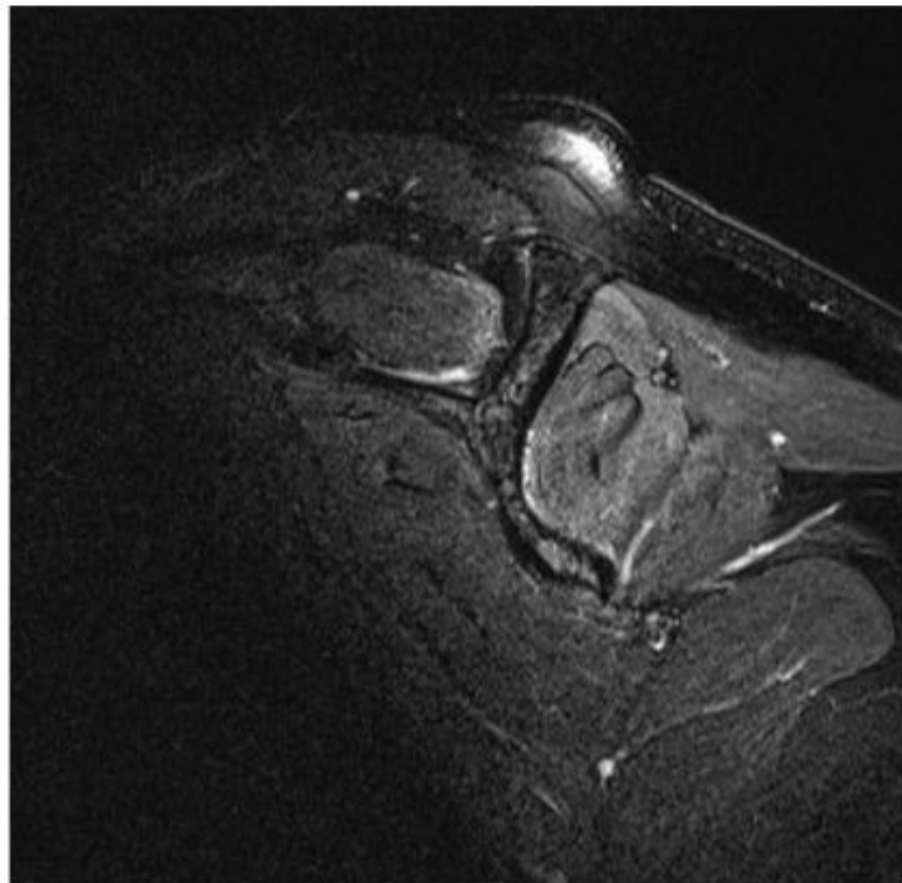
Case 1



Case 2

60 year old male, decreased shoulder movement, post MI, 2 months ago

Case 2



What is the Diagnosis

What is the differences in 2 cases ?

Answer

- CASE 1

- Classical parsonage tuner syndrome
- Affecting suprascapular nerve (supraspinatus and infraspinatus)

- CASE 2

- Parsonage turner syndrome
- changes less pronounced
- Affecting suprascapular nerve and also axillary nerve (rare). (supraspinatus, infraspinatus and deltoid)