

MICOD –19.12.2023

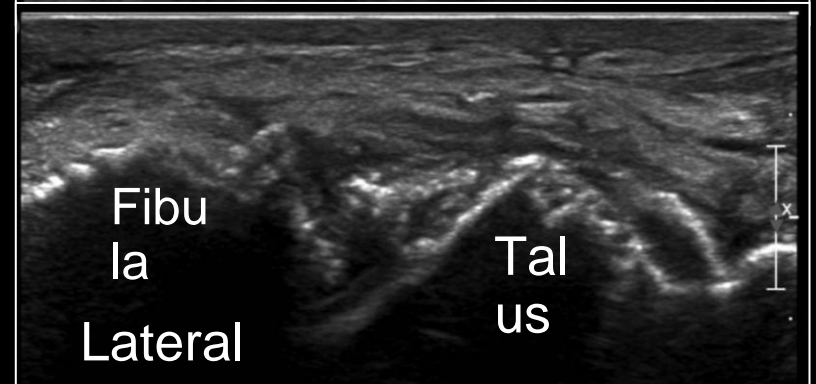
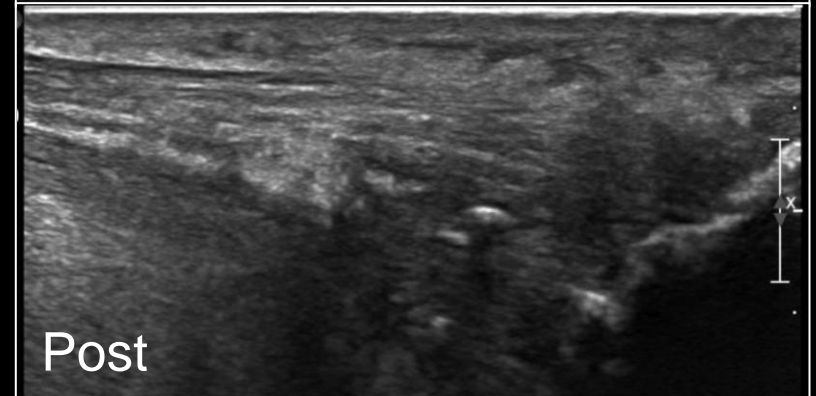
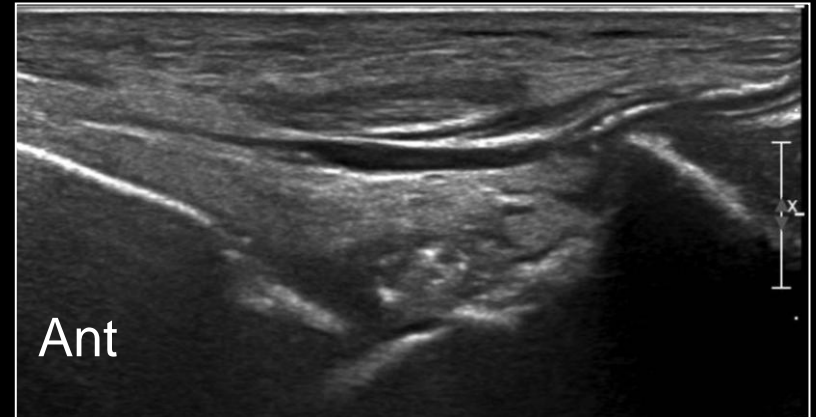
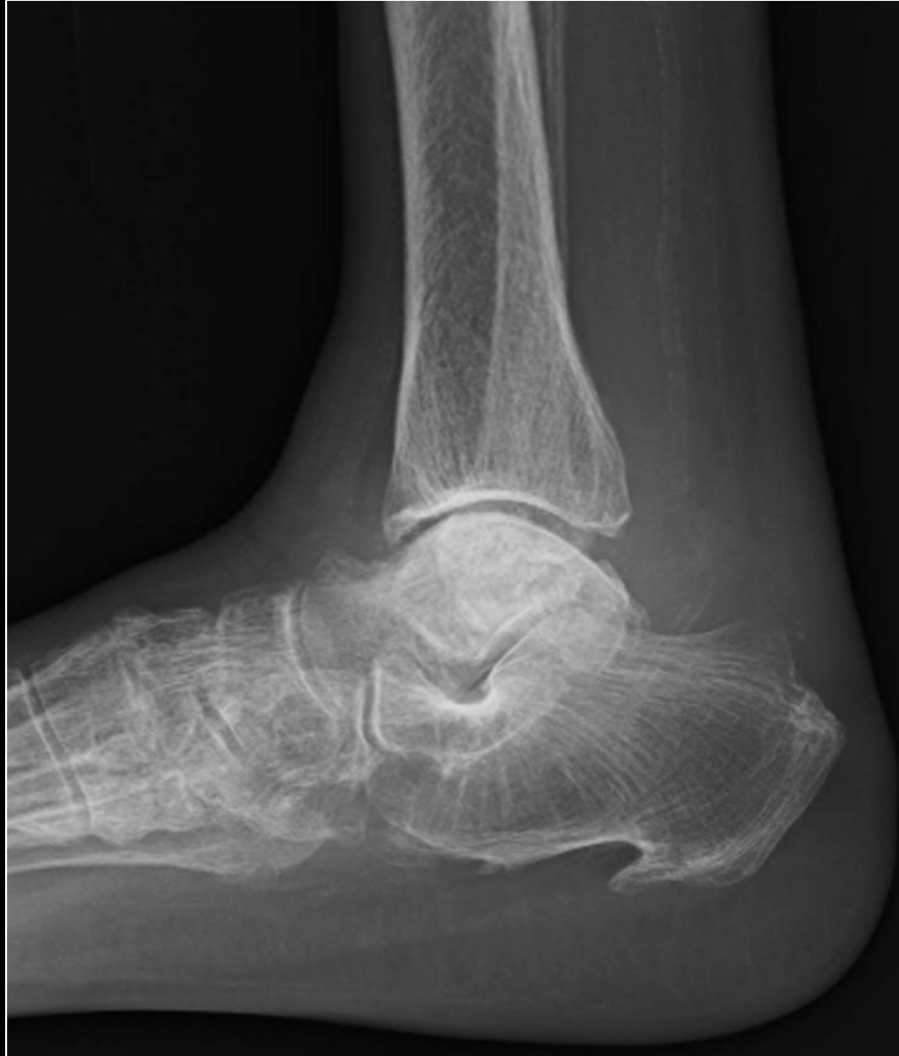Case contributor – Dr. Joseph K T, Dr. Madhavi K

# MI-COD

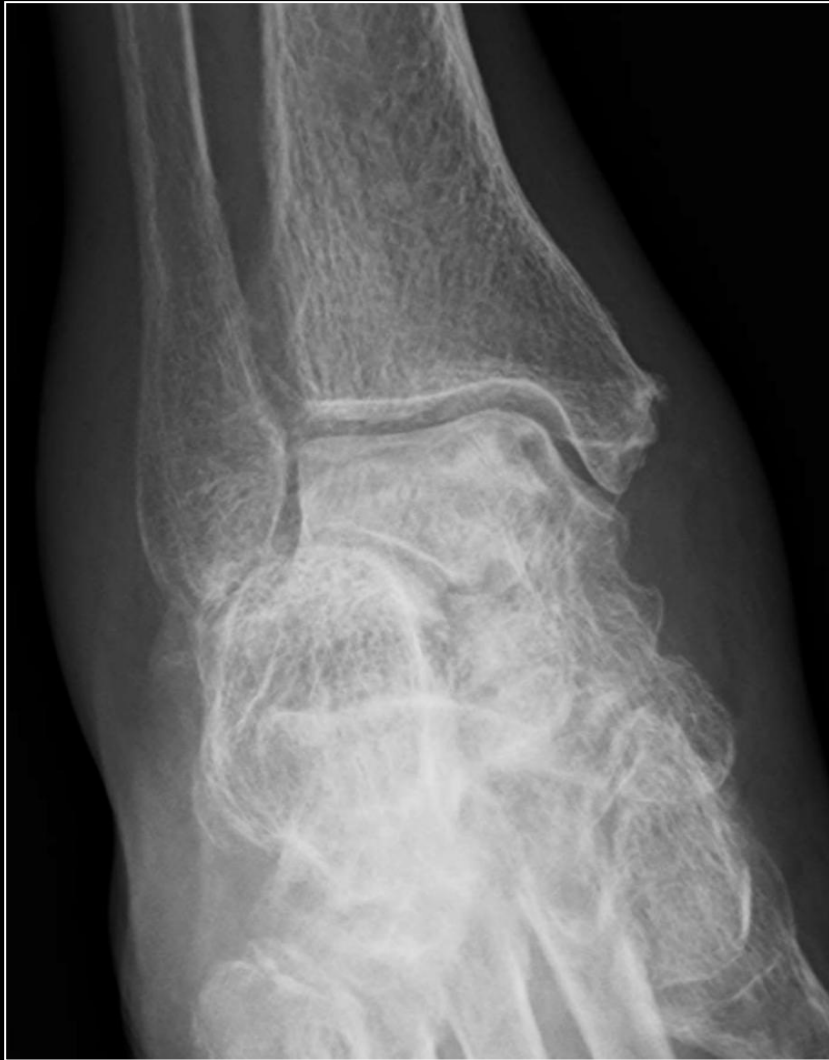MSS INDIA- Case Of the Day



60 year old lady with right ankle pain and swelling for 1 month. Recently diagnosed as CKD



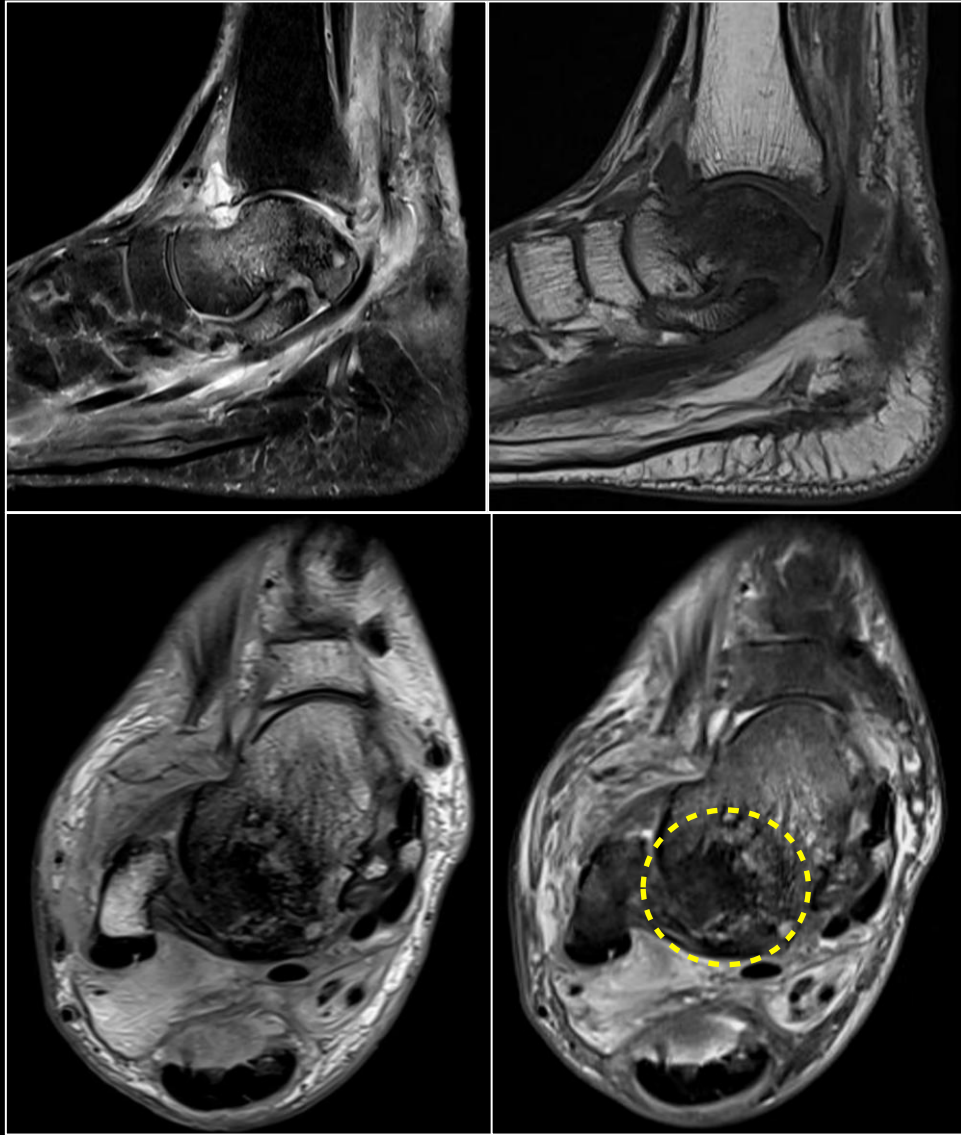
# Findings & Diagnosis



- ▶ Diffuse osteopenia with periostitis (better seen in ultrasound images).
- ▶ Ankle joint mild effusion and synovitis.
- ▶ Diffuse edema in muscle and subcutaneous plane.

*-These imaging features and history of CKD suggests metabolic bone disease due to end stage renal failure.*

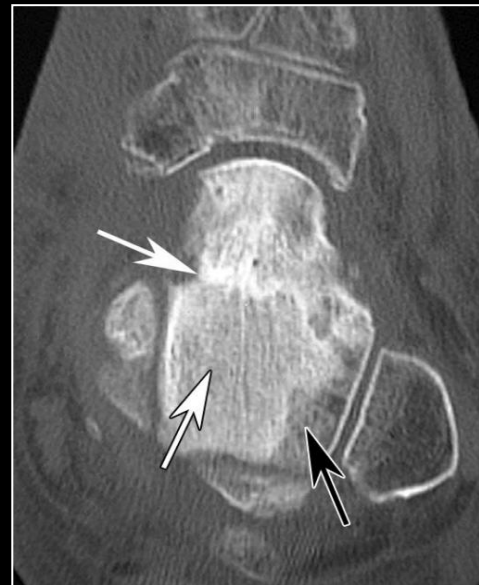
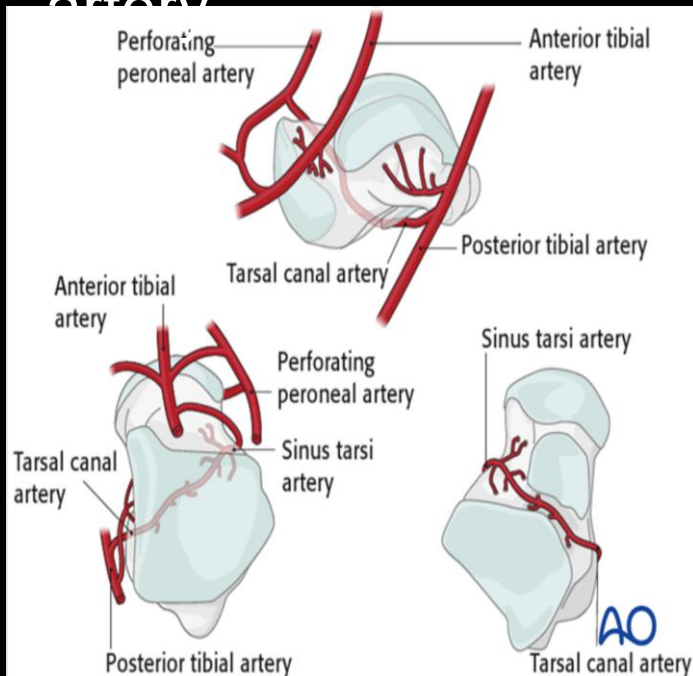
- ▶ Marked sclerosis of the entire dome of talus with mild collapse - *Avascular necrosis* [steroid intake].



- ▶ MRI done later demonstrates the extent of the avascular necrosis of the talus.

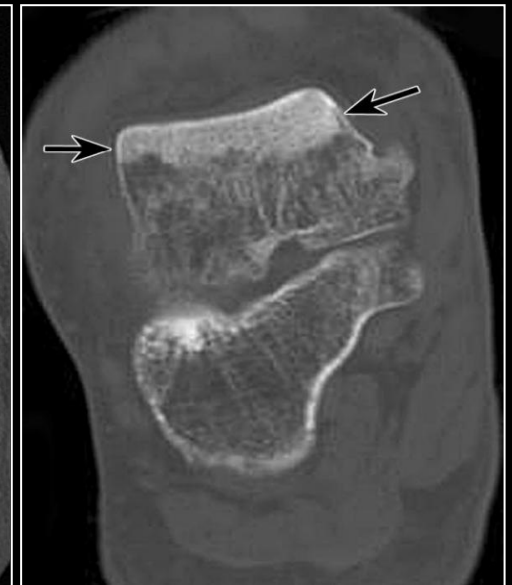# Talus AVN

- ▶ Non-traumatic / traumatic causes resulting in interruption of any part of anastomotic vascular loop between posterior and anterior tibial artery through the tarsal canal artery



AVN involving most of talus following fracture

<https://doi.org/10.1148/rq.252045709>



Talar dome AVN caused by talar neck fracture