


MICOD – 12.12.2023

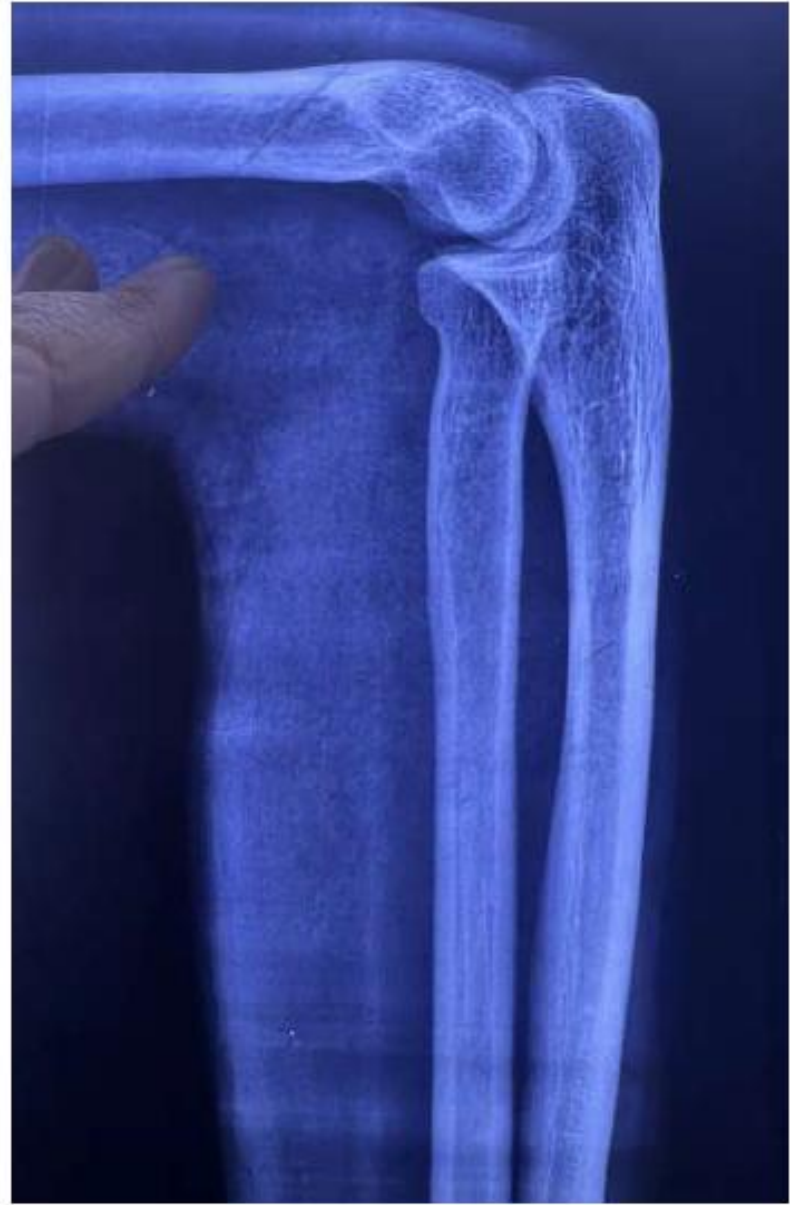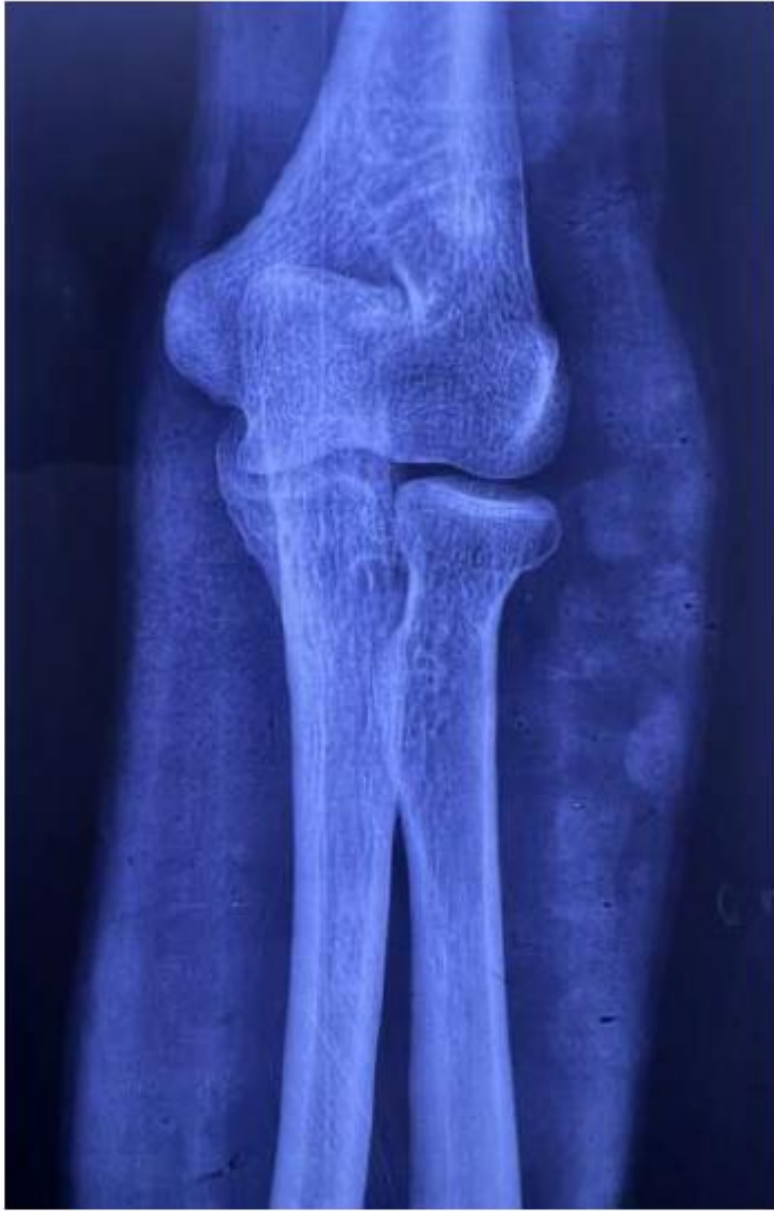Case contributor – Dr. Shaafiya Ashraf

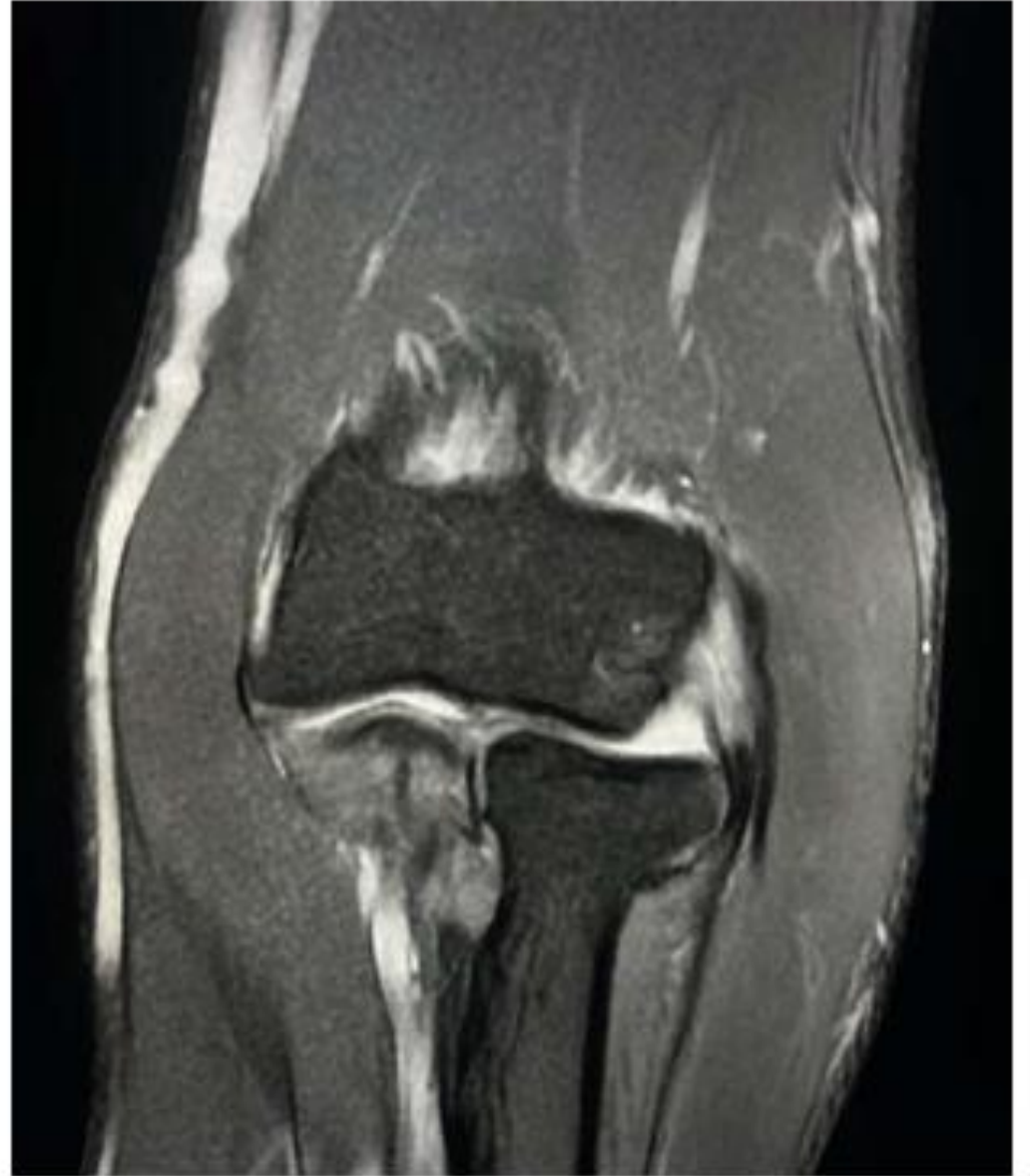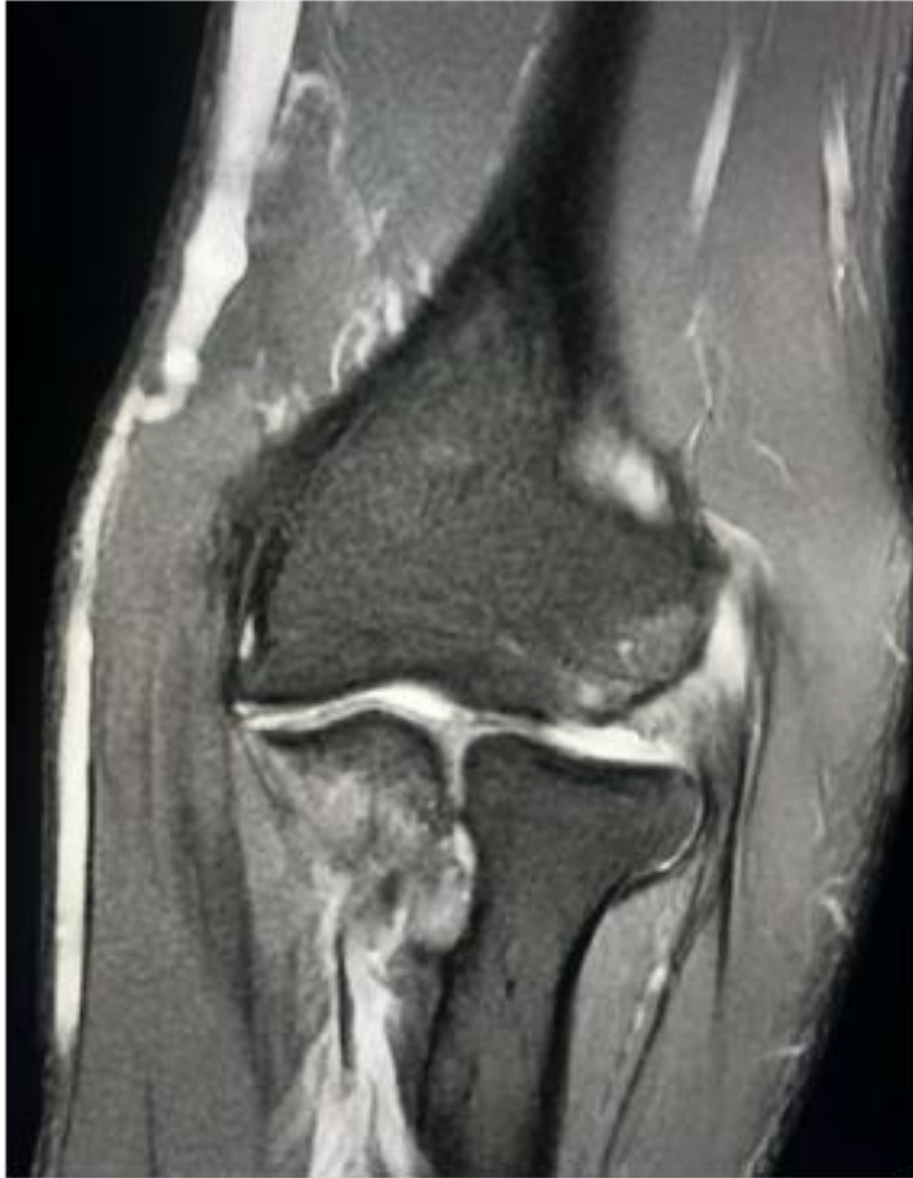MI-COD

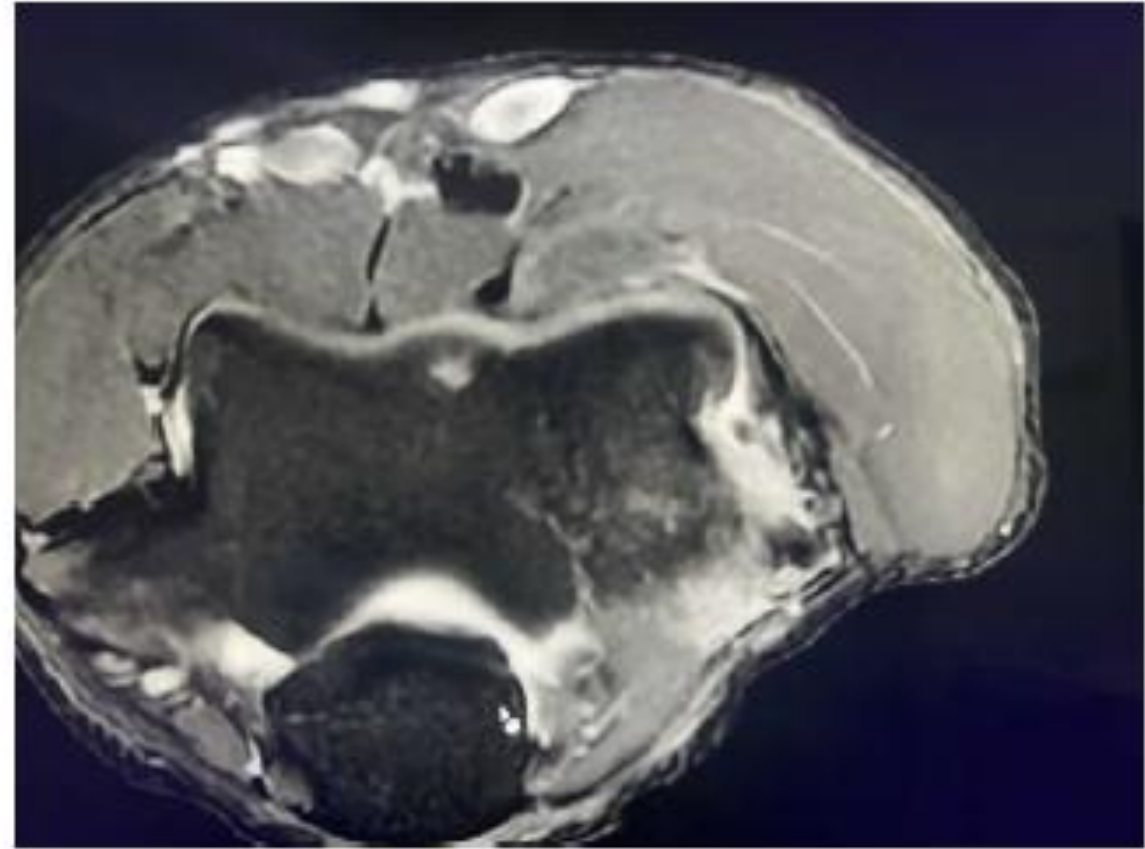
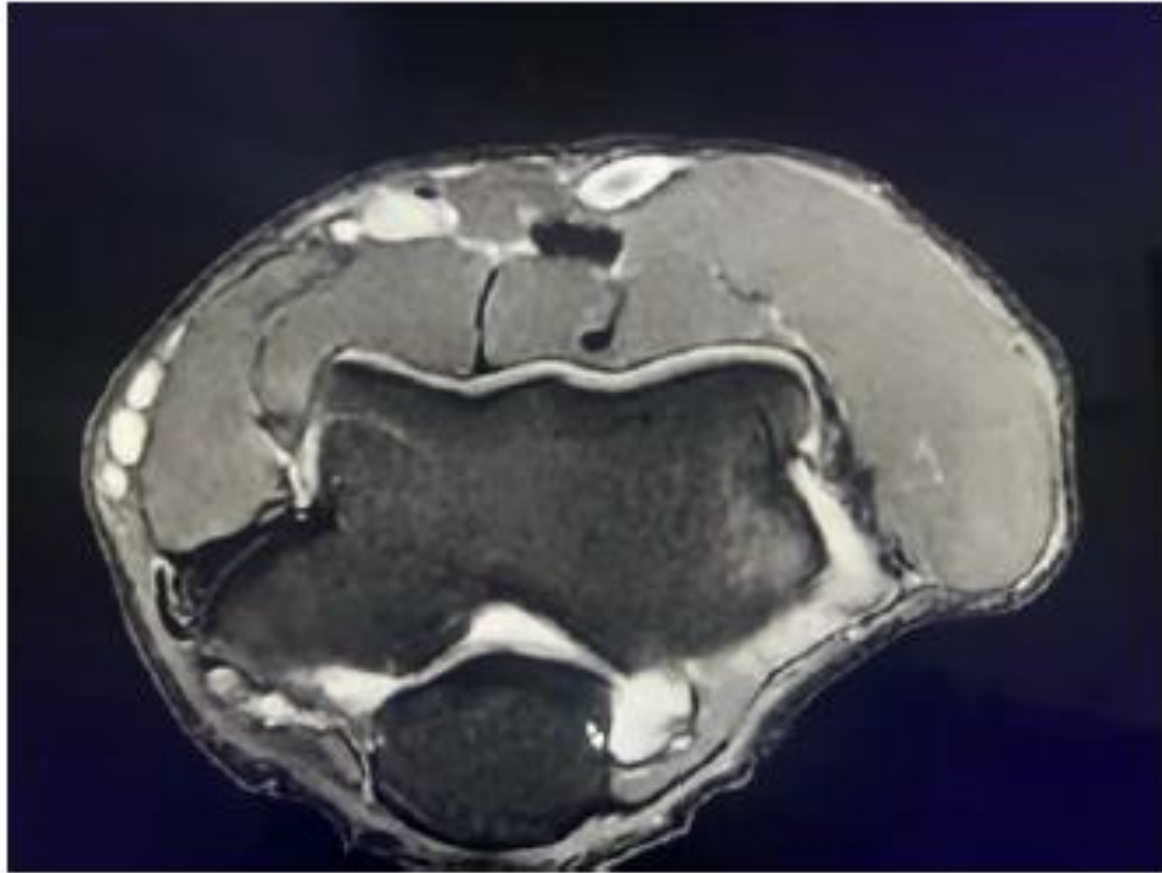
MSS INDIA- Case Of the Day



- 42Y/F
- Elbow pain -2 years
- Pain on extension and twisting movements.







- Thickened common extensor origin with fraying of deep fibres
- Lateral epicondyle marrow edema

LATERAL EPICONDYLITIS- tennis elbow