

MICOD – 15/12/2023

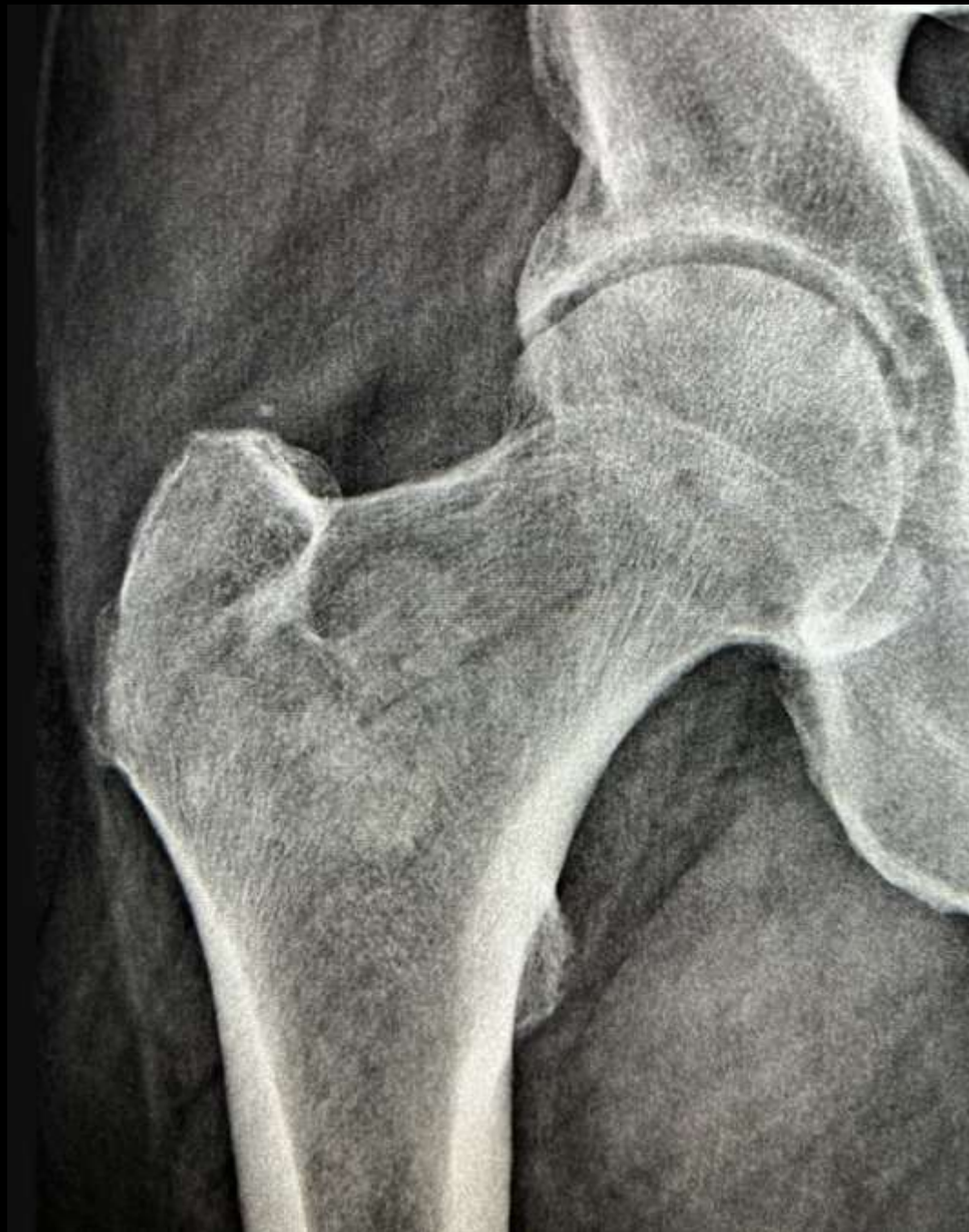Case contributor – Dr. Harun Gupta (MSK Teaching Room)

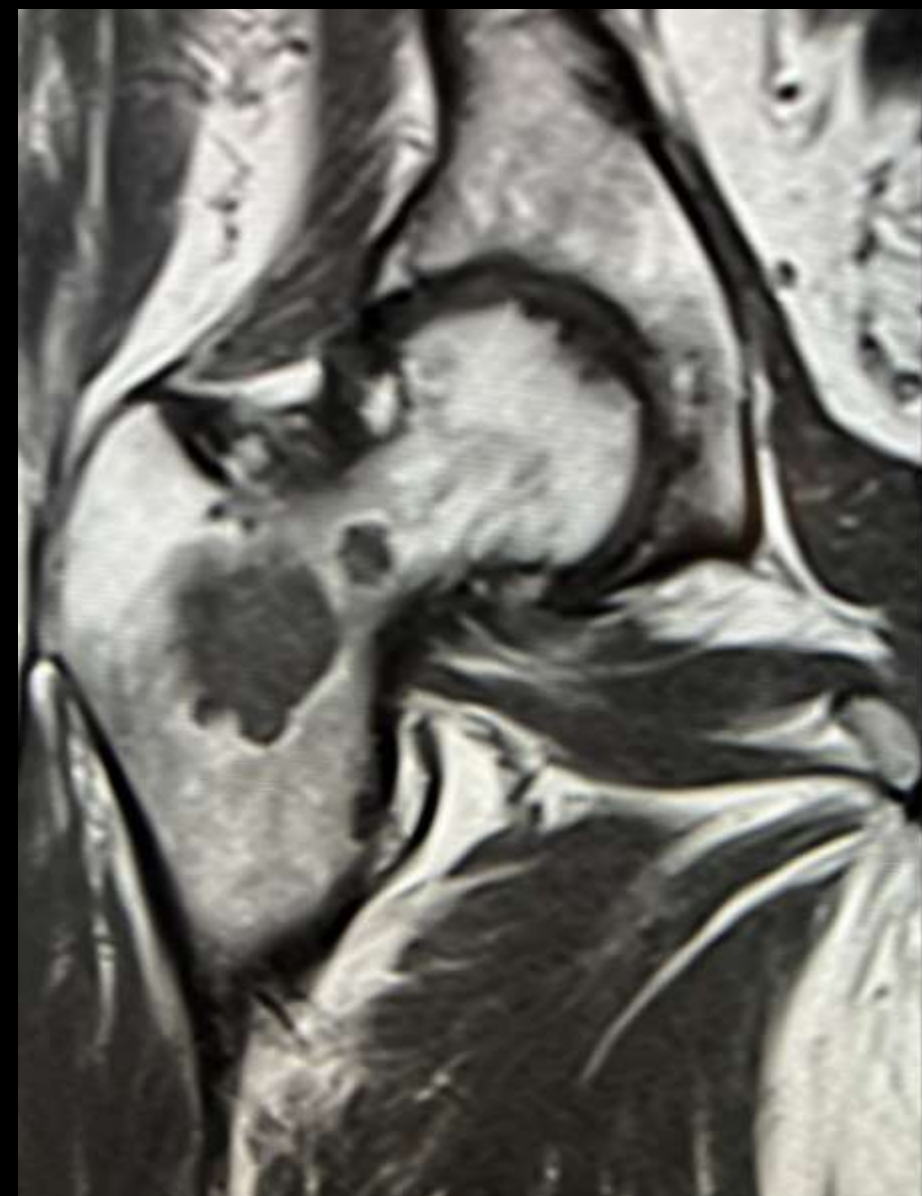
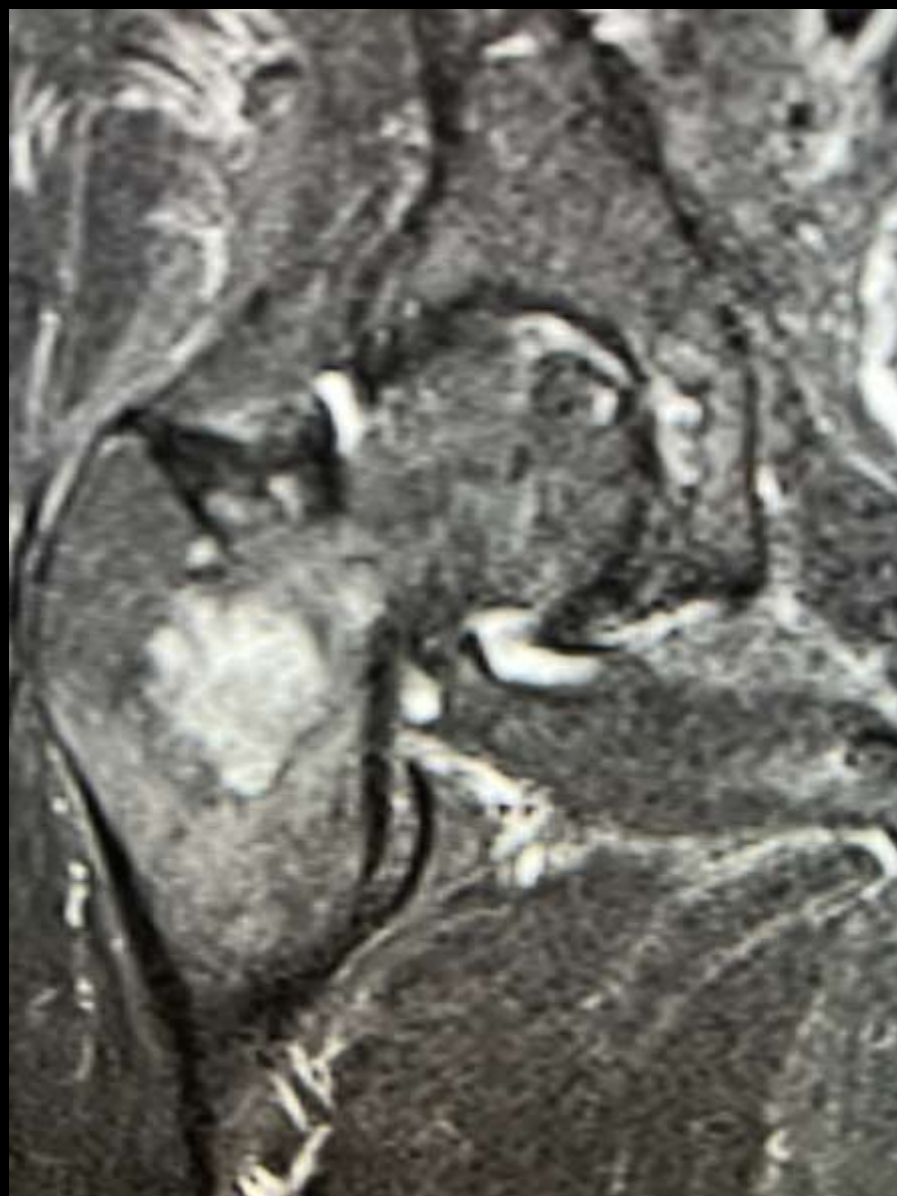# MI-COD

MSS INDIA- Case Of the Day



66 yr M hip pain





# 66 yr M... Answer

- **Sclerotic lesion neck / intertrochanteric region of femur**
- **Hip degenerative changes**
  
- **Metastatic disease from Prostatic cancer**