

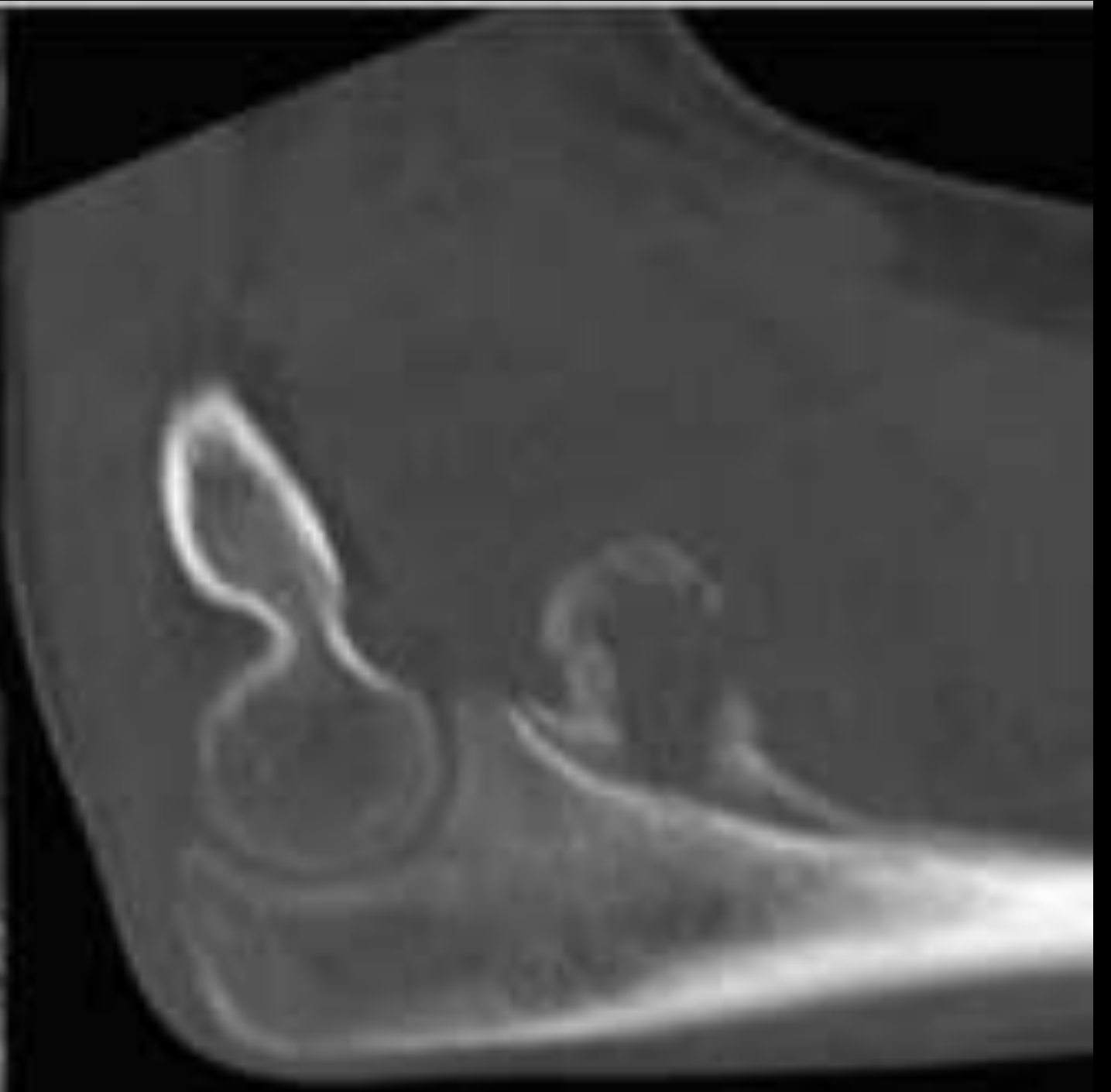
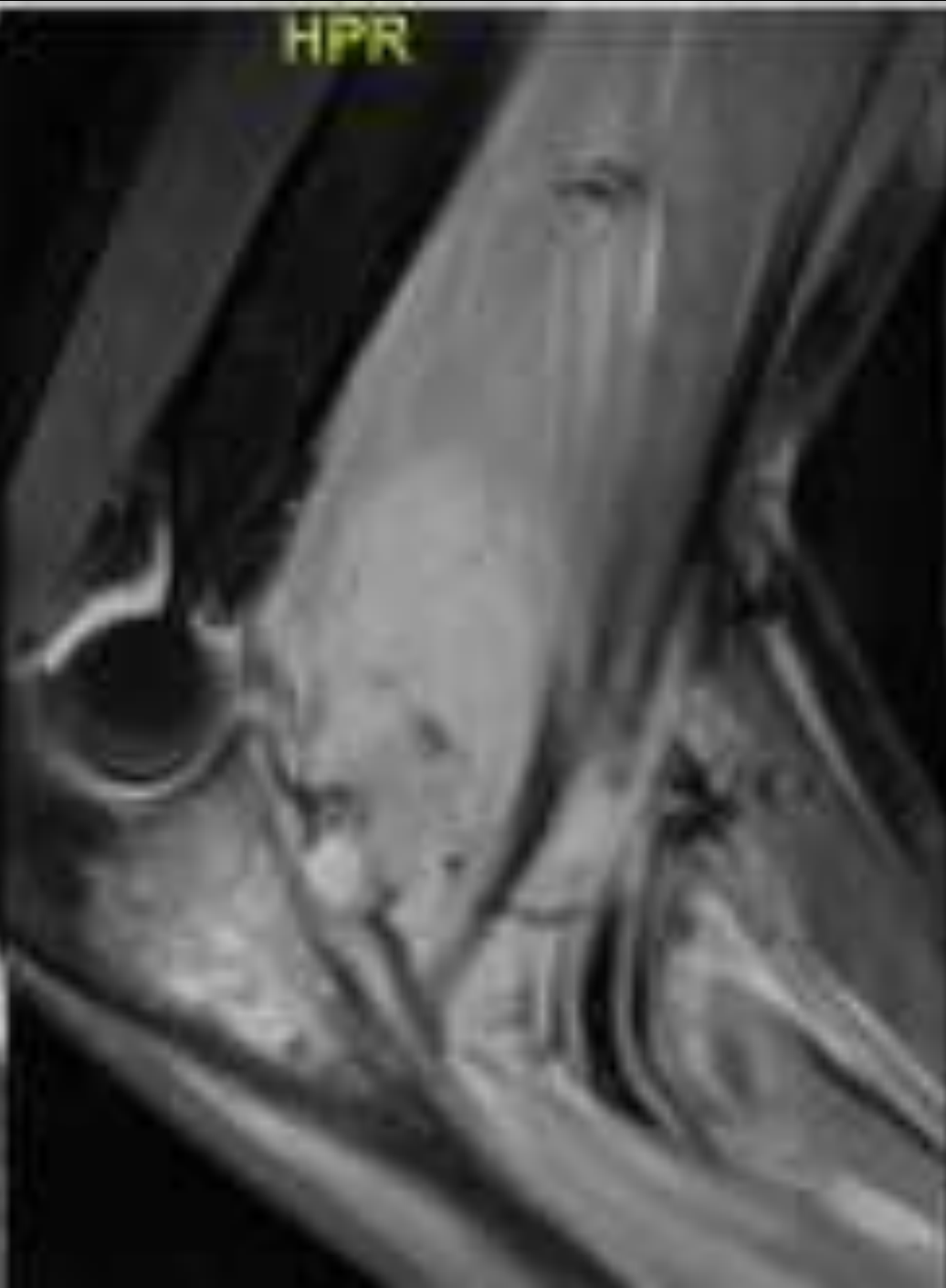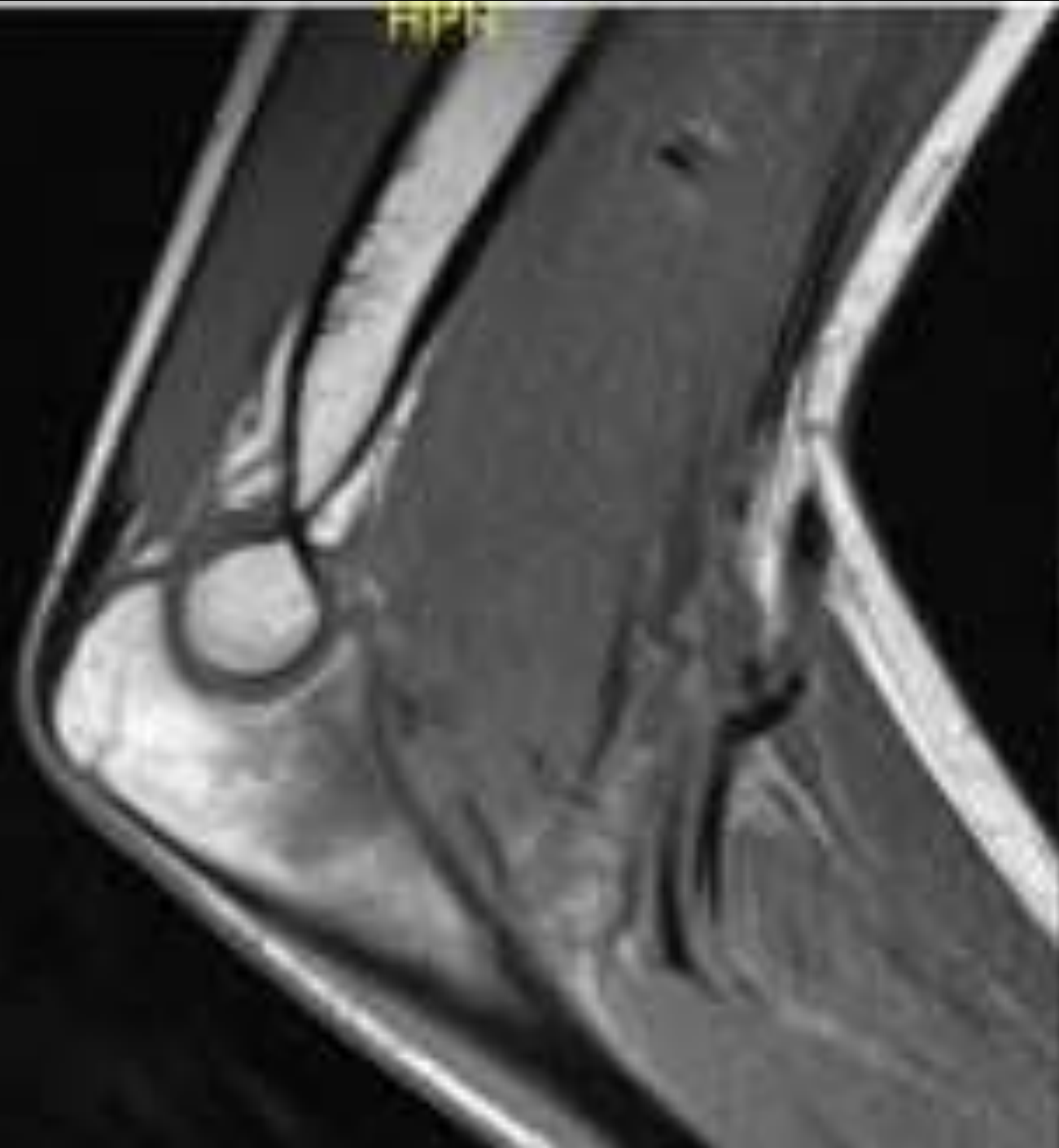
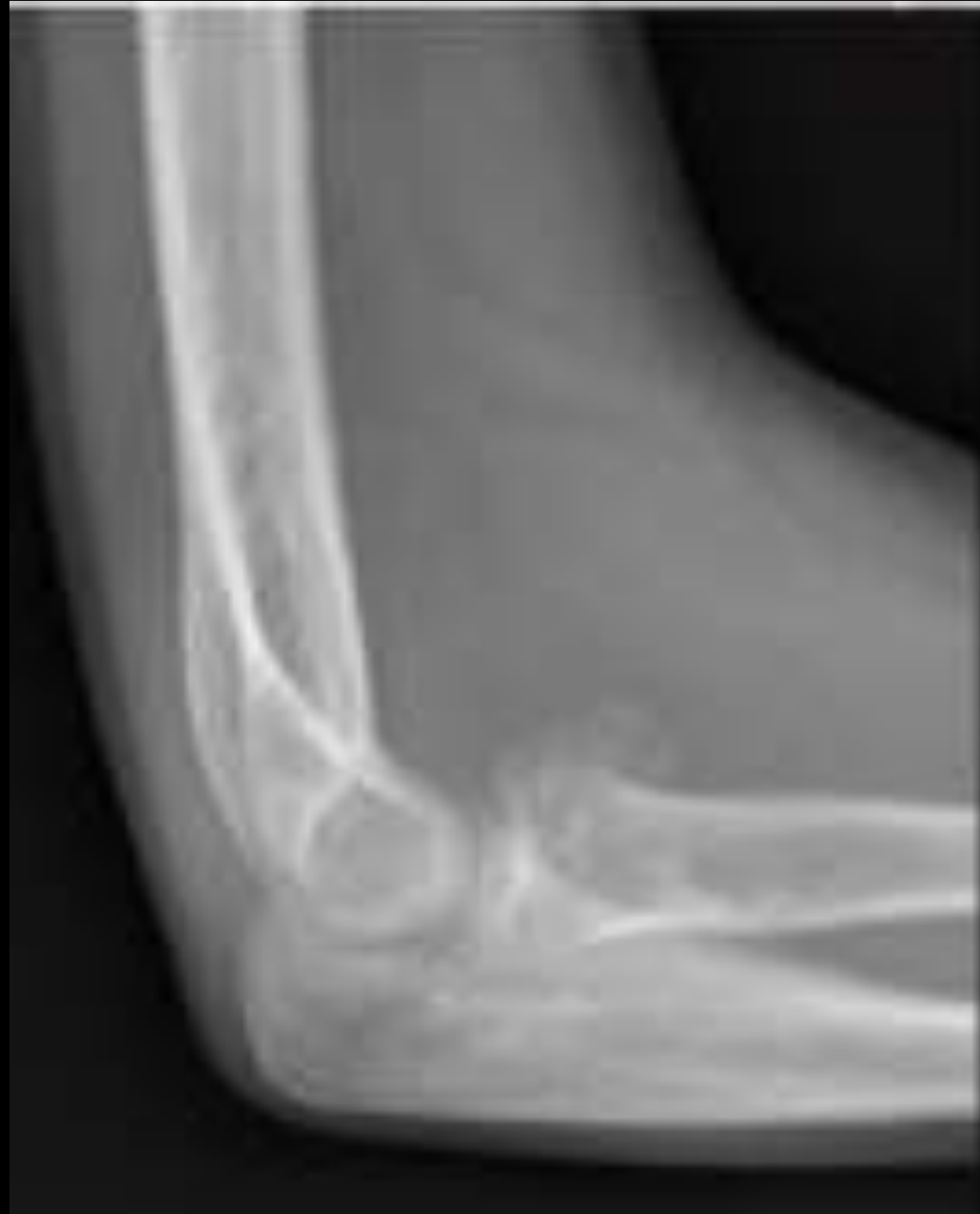MICOD – 06/12/2023

Case contributor – Dr. Rajesh Botchu

MI-COD

MSS INDIA- Case Of the Day





Periosteitis Ossificans

Article published online: 2023-07-14



Original Article

Periosteitis Ossificans: Largest Case Series with Review of Literature

Ahmed Saad¹ Karthikeyan P. Iyengar² Vineet John Kurisunkal¹ Neha Nischal³ A.M. Davies³
Rajesh Botchu³

Periosteitis ossificans (PO) are rare, benign ossifying surface lesions characterized by the centripetal ossification with osseous and soft-tissue edema. Their clinicoradiological appearances can easily mimic those of more sinister or infective surface lesion. It is akin to myositis ossificans.