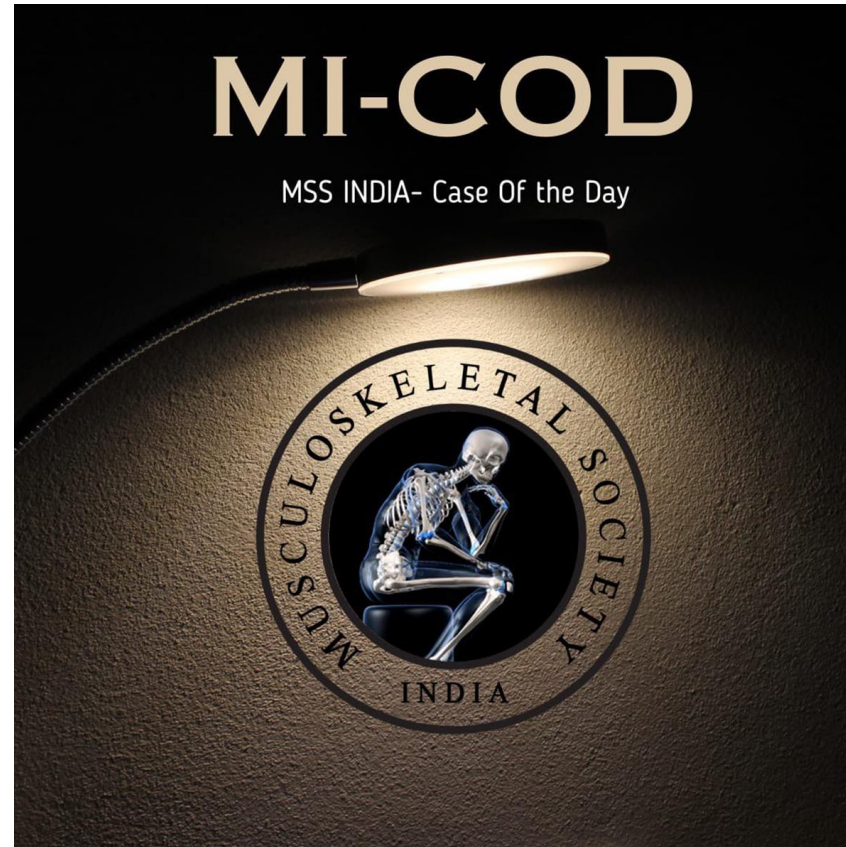


MICOD -31/08/2023

Case contributor – **Dr.Harun Gupta**



# Young Elite Cyclist with wrist pain Case 2

Dr Harun Gupta  
[@mskteachingroom](#)

- Osteoid Osteoma Hamate

Learning points

Sometimes no calcification in the nidus esp when cortical location