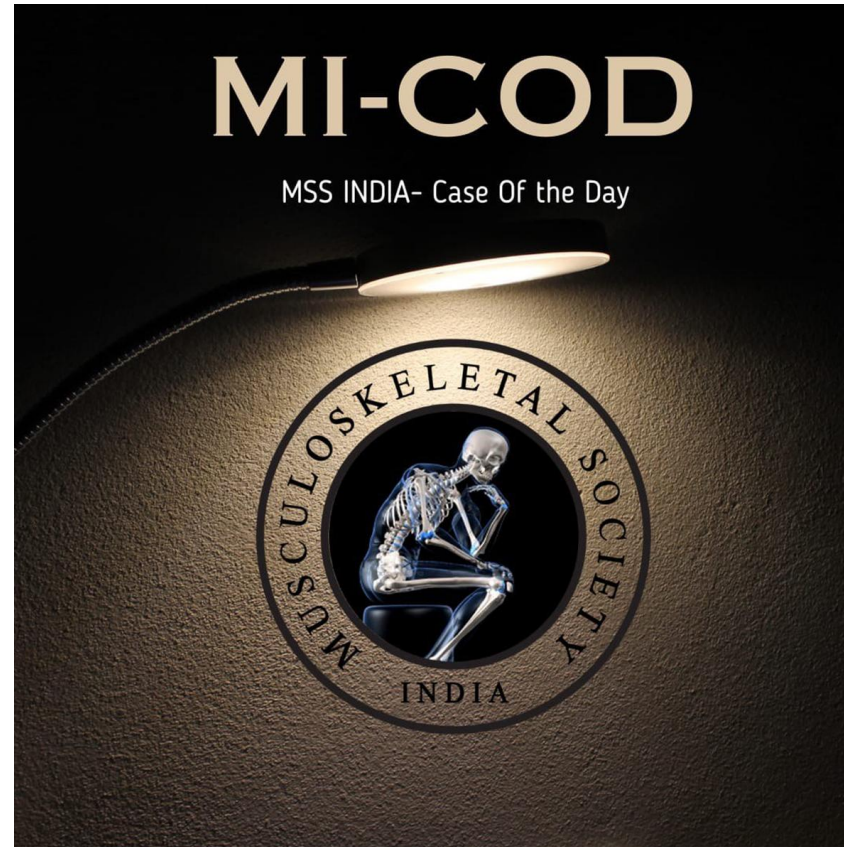


MICOD -30/08/2023

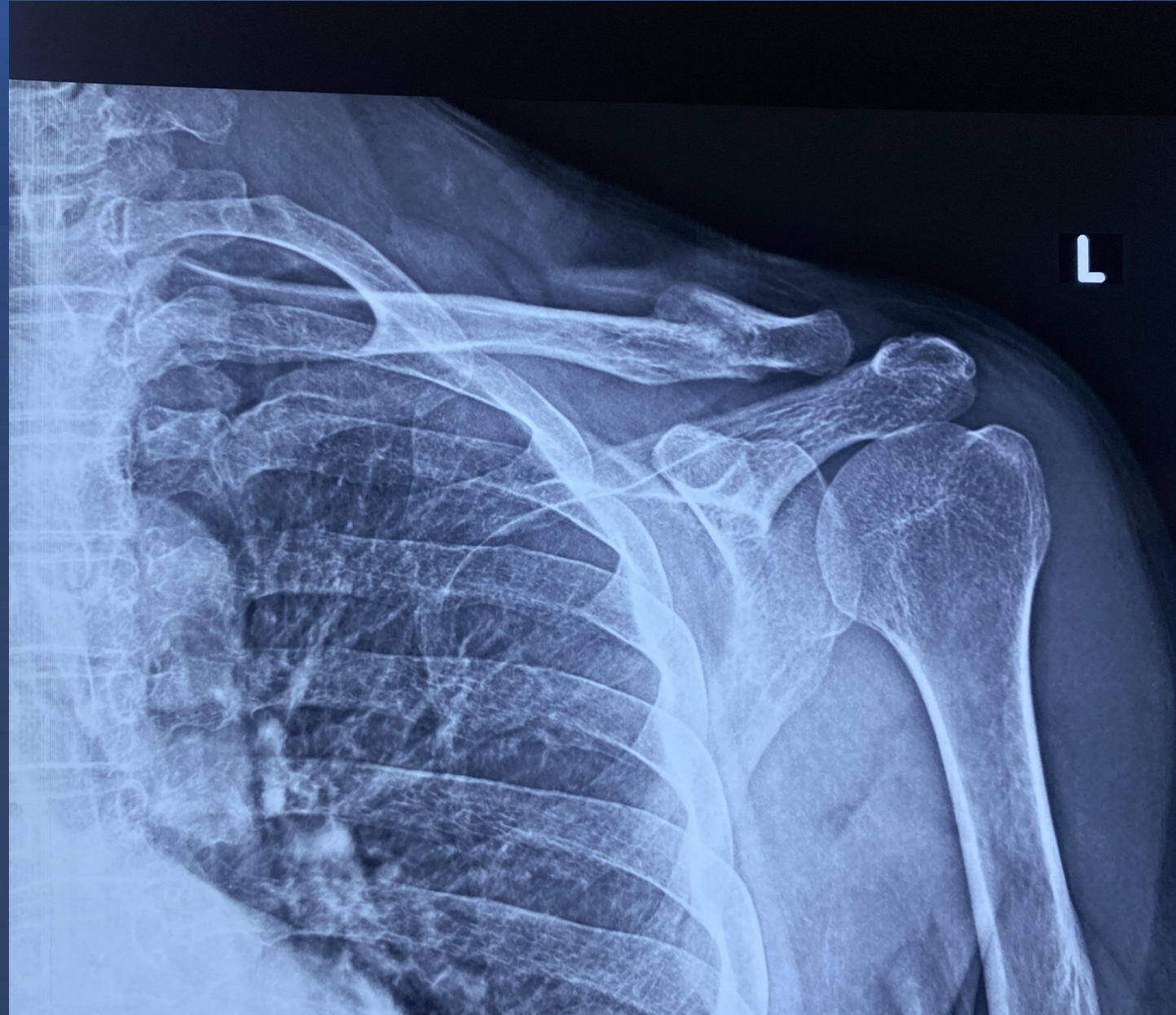Case contributor – **Dr.Joban Babhulkar**

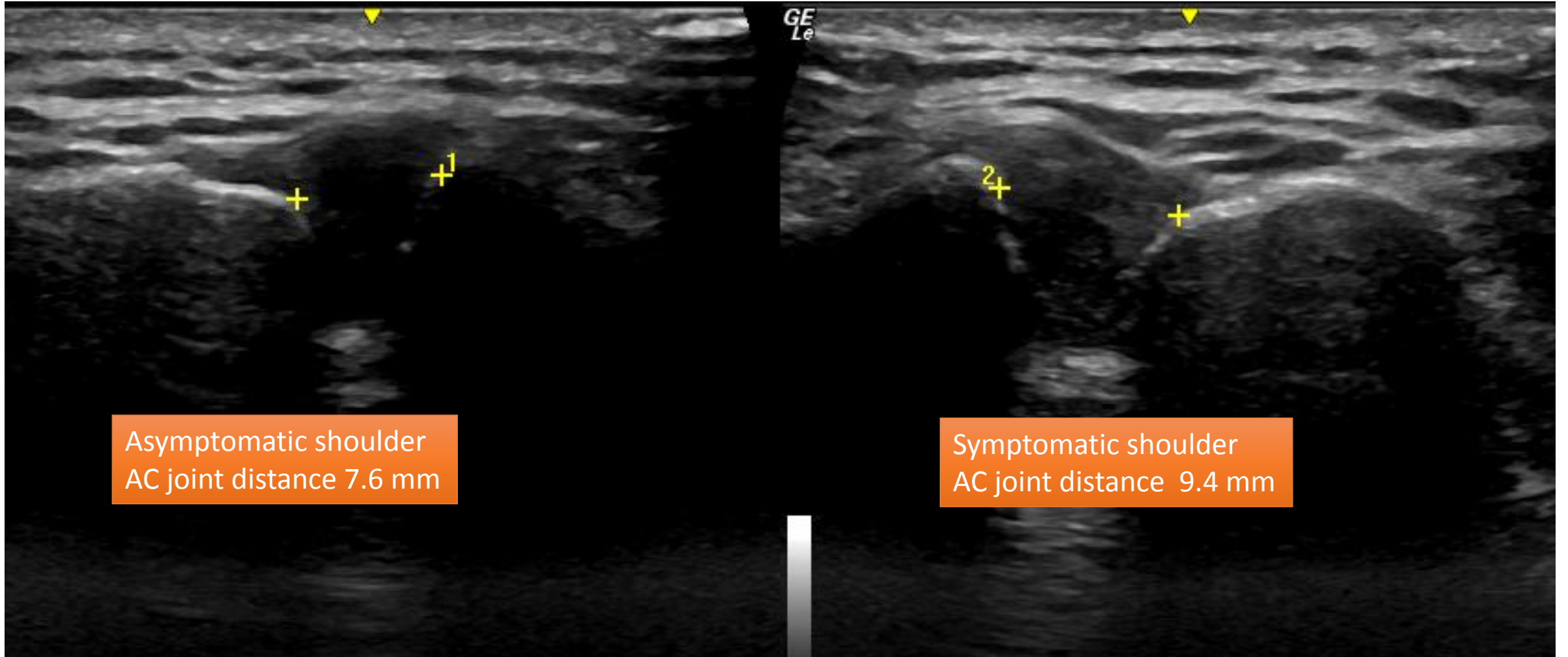


58 y/o man was on conservative management for fracture lateral end of clavicle.

Has severe pain on shoulder movement 6 weeks post injury

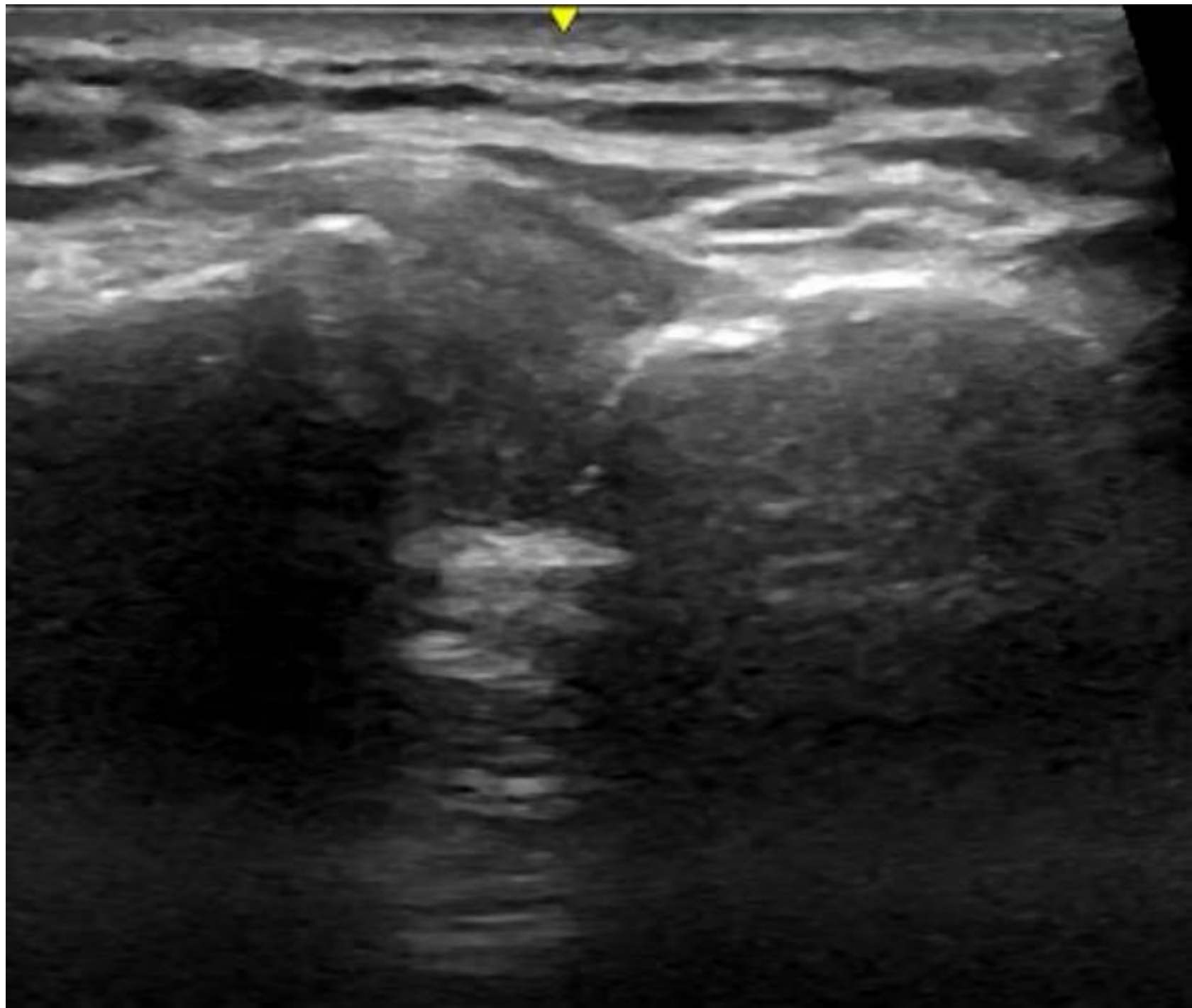
Zanca view 6 weeks after injury





Asymptomatic shoulder
AC joint distance 7.6 mm

Symptomatic shoulder
AC joint distance 9.4 mm



Questions

Grade of injury to AC joint ?

Nature of instability

Any possible ligament injury ?

Usual management?

Grade 2 injury to acromioclavicular joint

Dynamic horizontal instability where there is posterior translation of the clavicle respect to the acromion on dynamic scanning

Usually involves tear of the superior acromioclavicular ligament

In absence of any other abnormality , management will be conservative

Dynamic USG is excellent modality for diagnosing the same