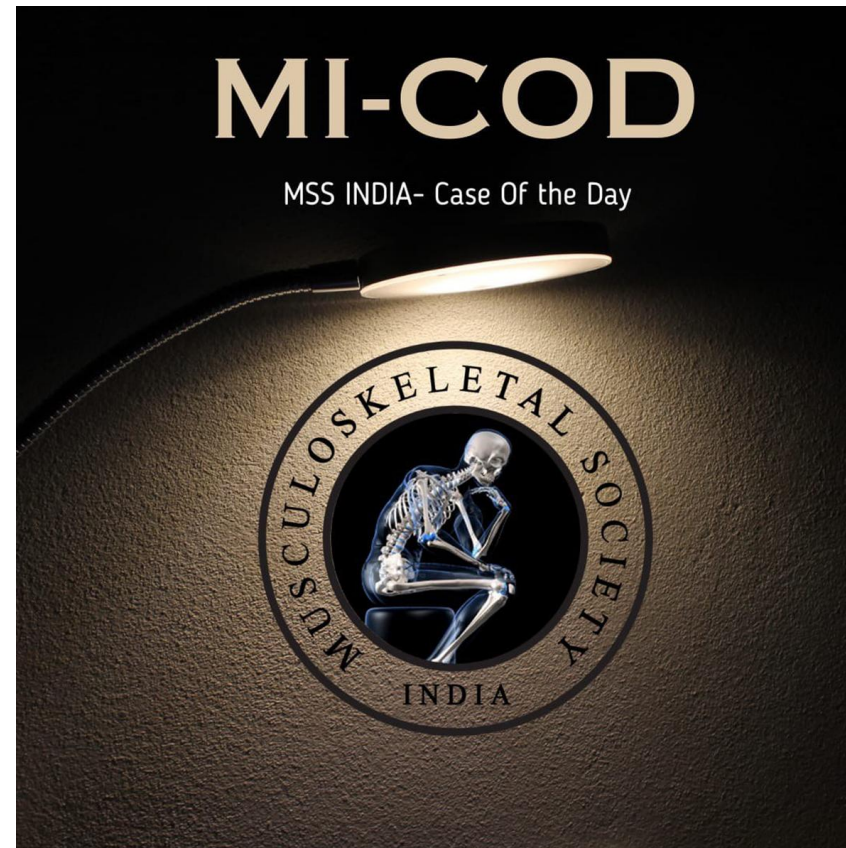


MICOD -29/08/2023

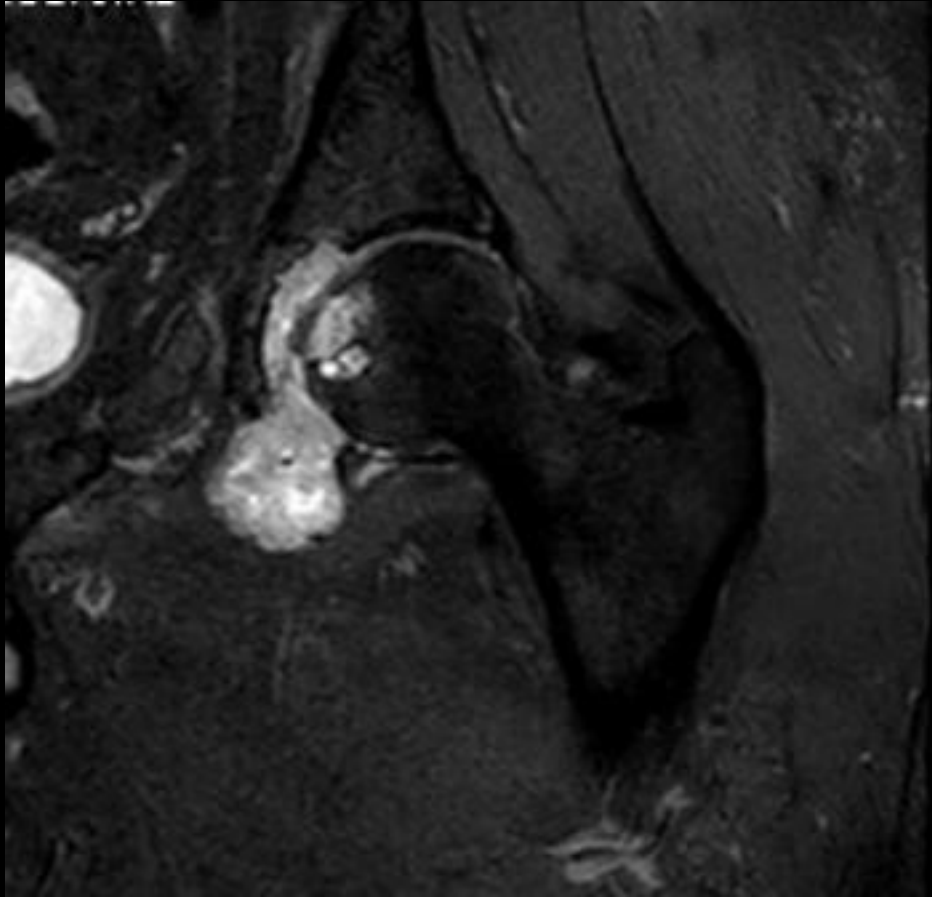
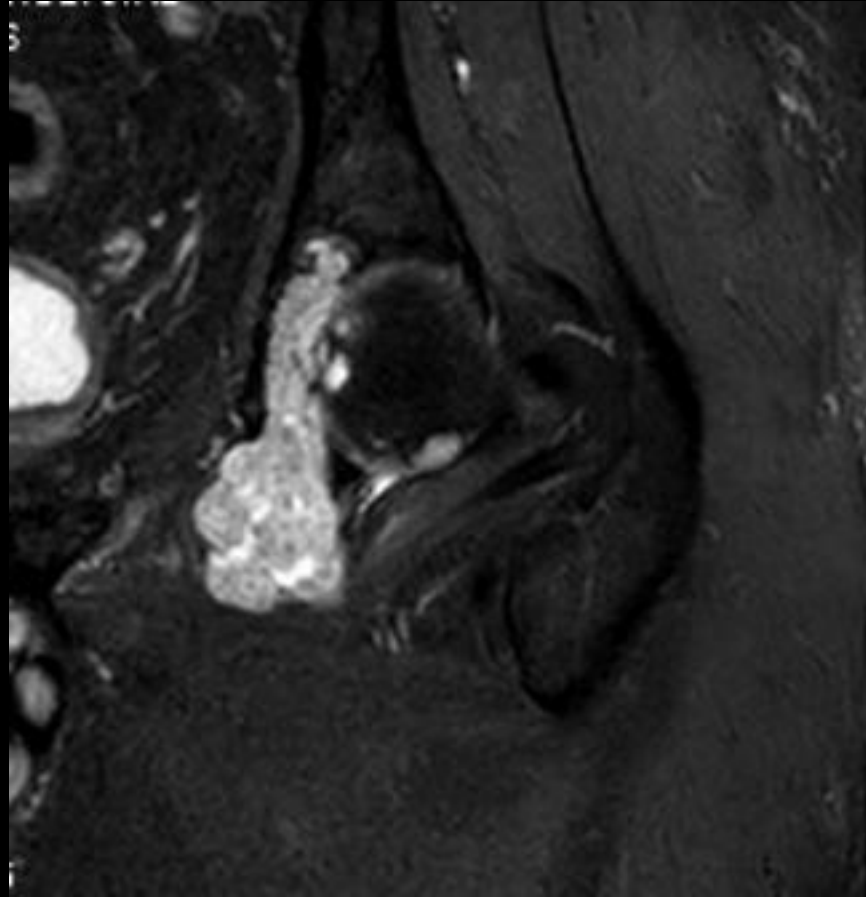
Case contributor – **Dr Amogh VN**

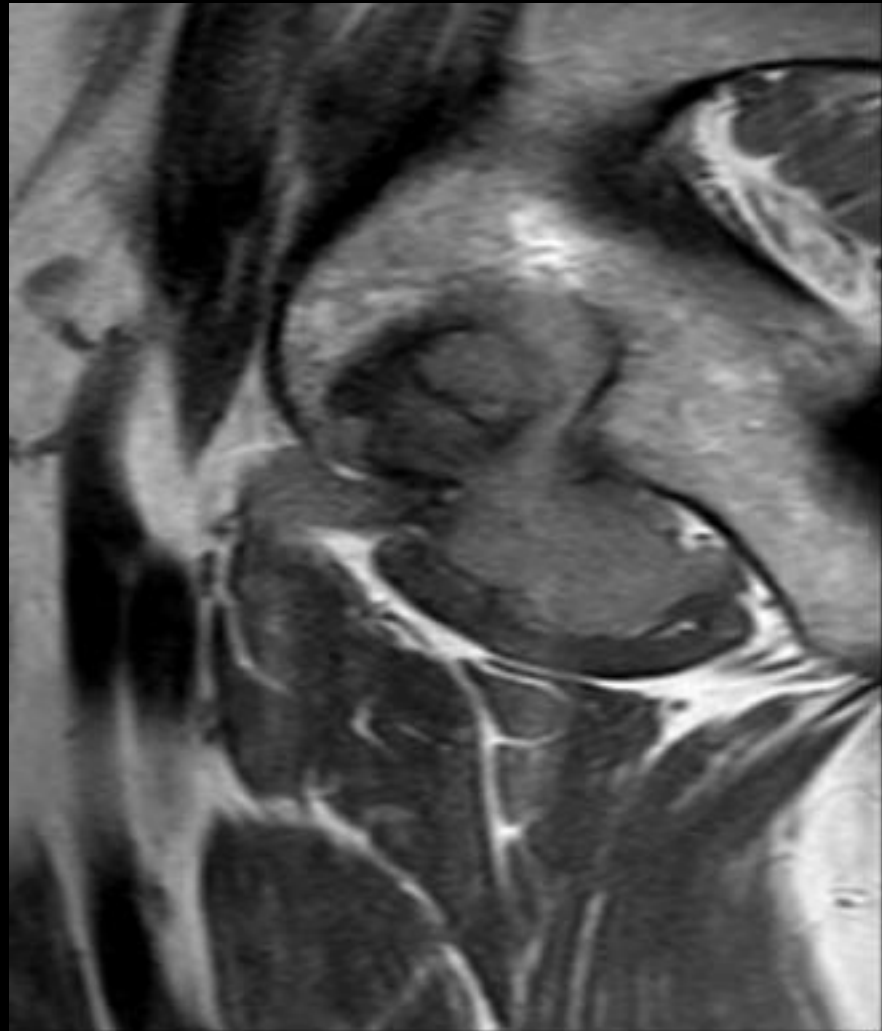
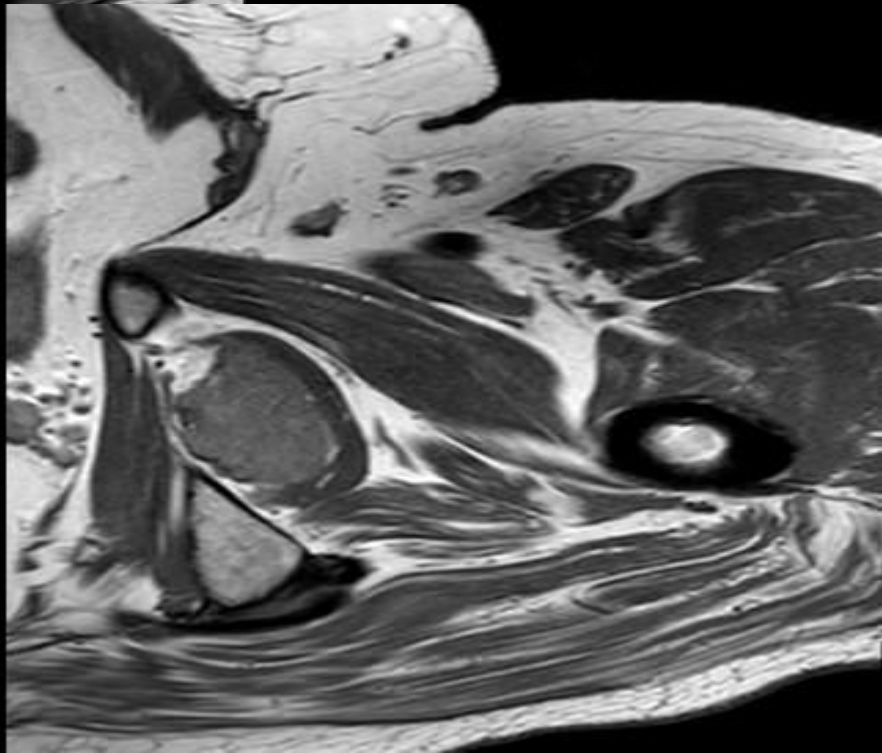
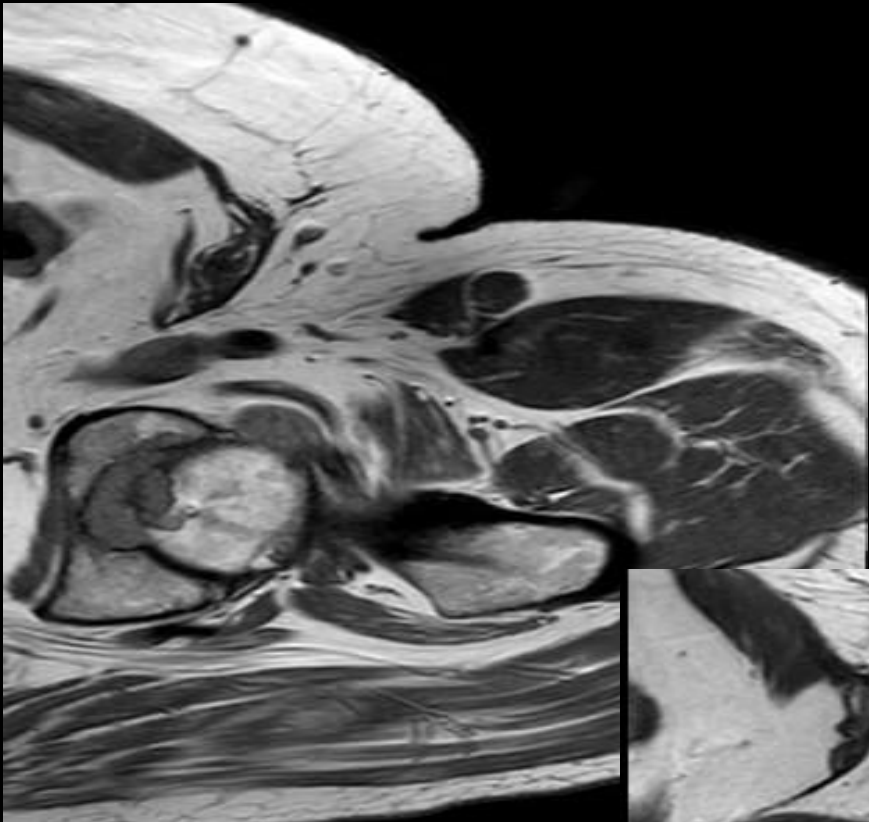
Aster RV hospital

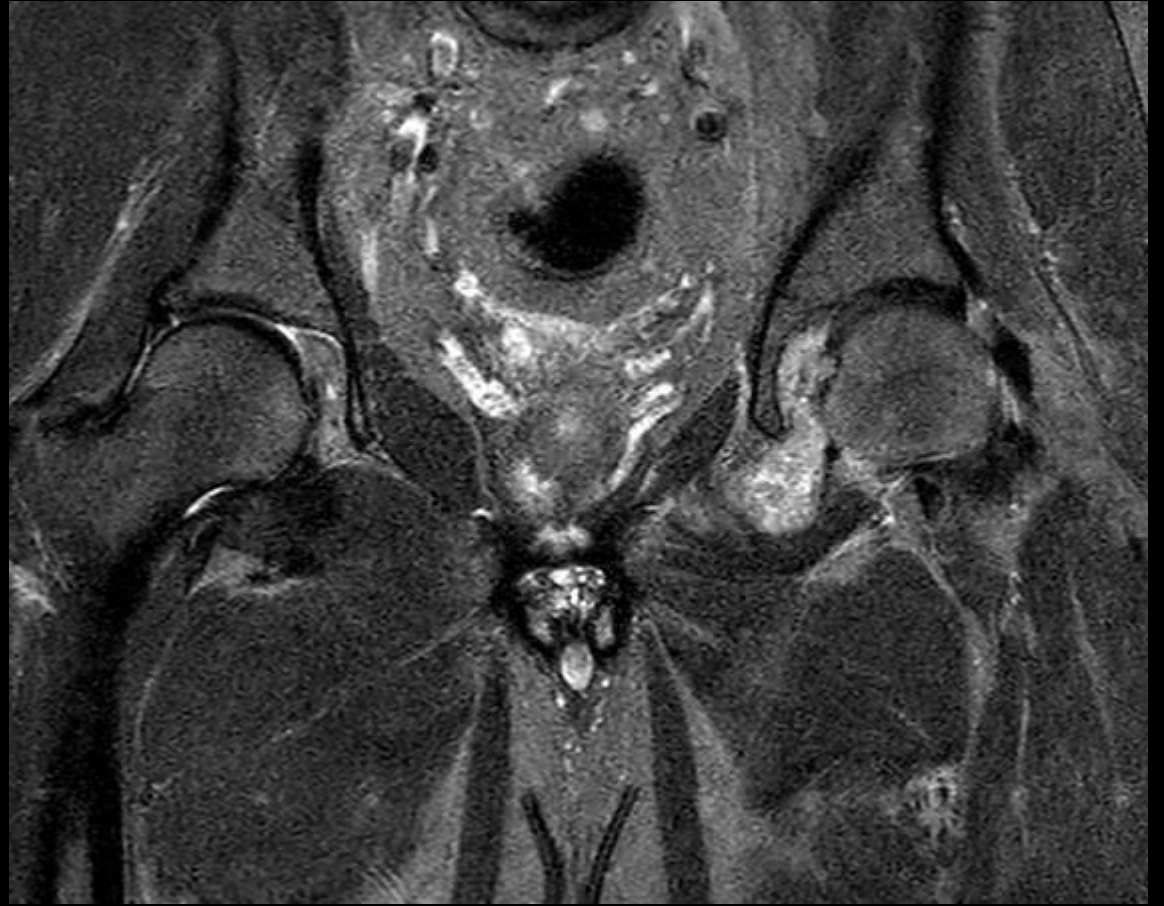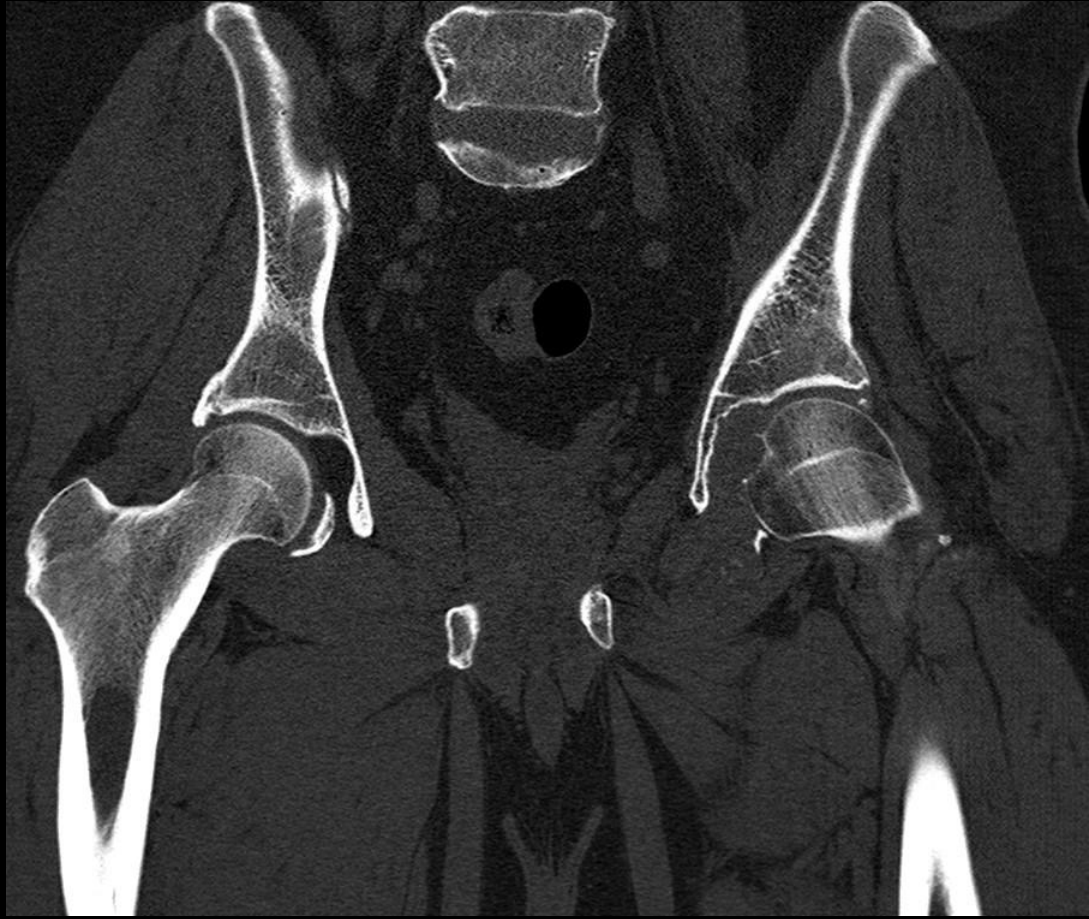
Bengaluru



62 year old male patient with left hip limp.







Discussion

Operative notes: Patient underwent near total excision of the tumor without prior biopsy.

Surgical specimen report

Low grade cartilaginous tumor with mild cytological atypia. No malignancy. Possibility of chondromatosis.