


**MICOD 27/09/2023**

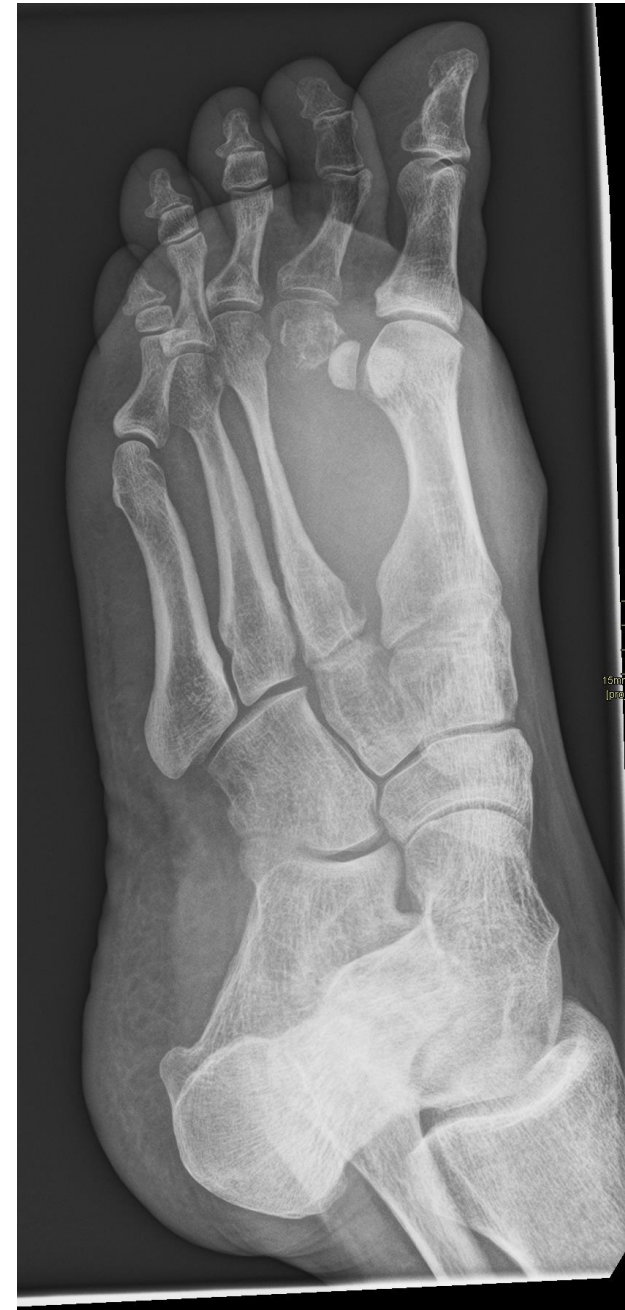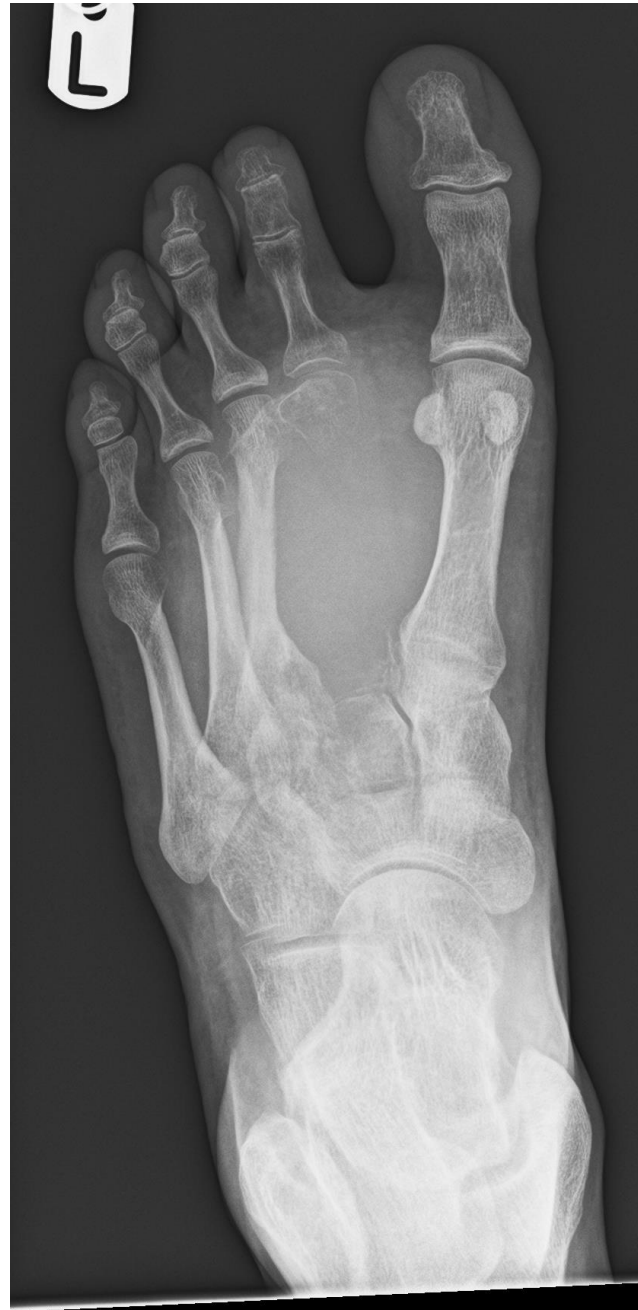**Case Courtesy: Dr. Harun Gupta (@mskteachingroom)**

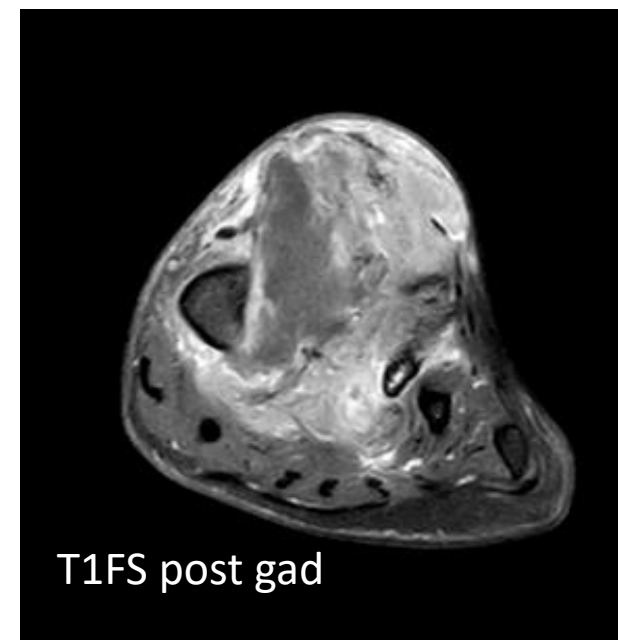
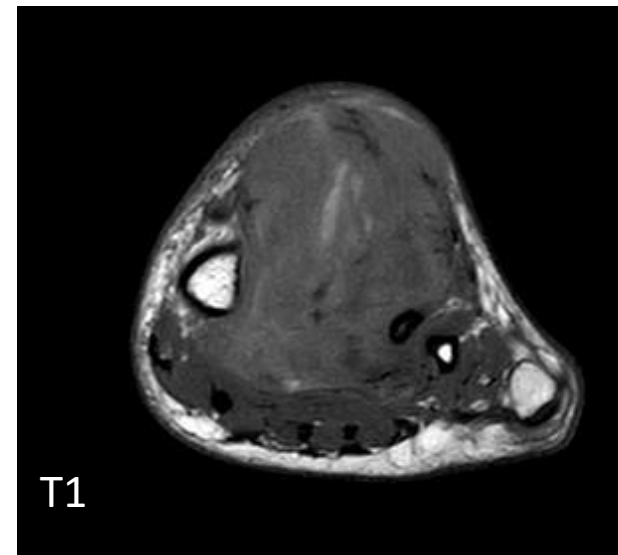
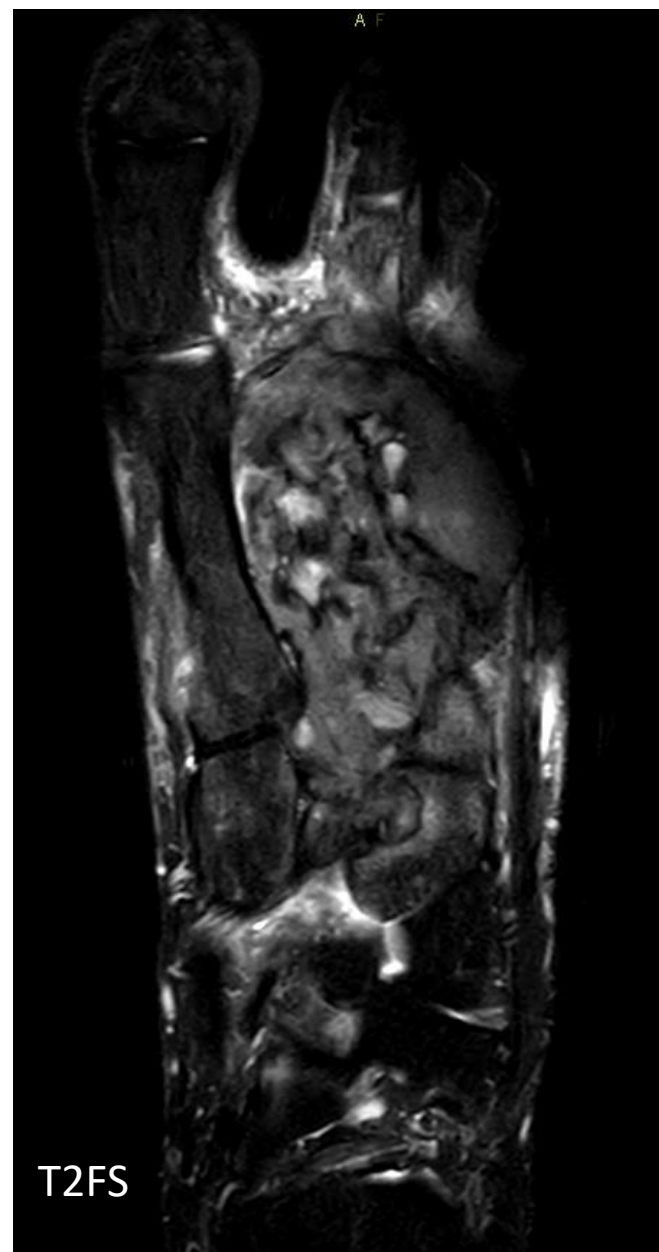
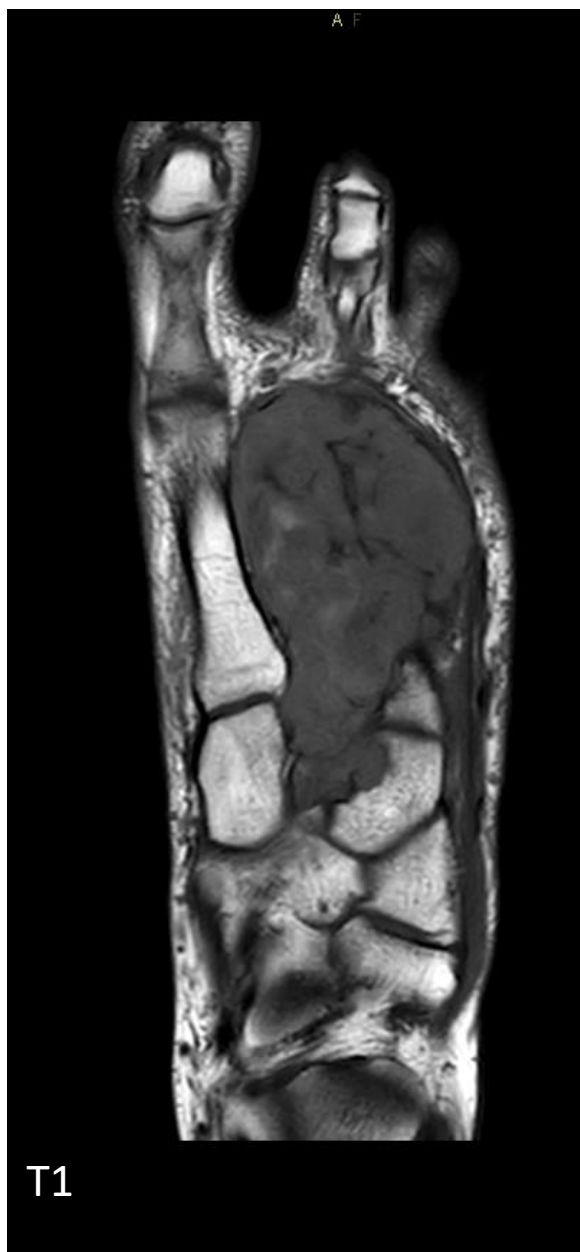

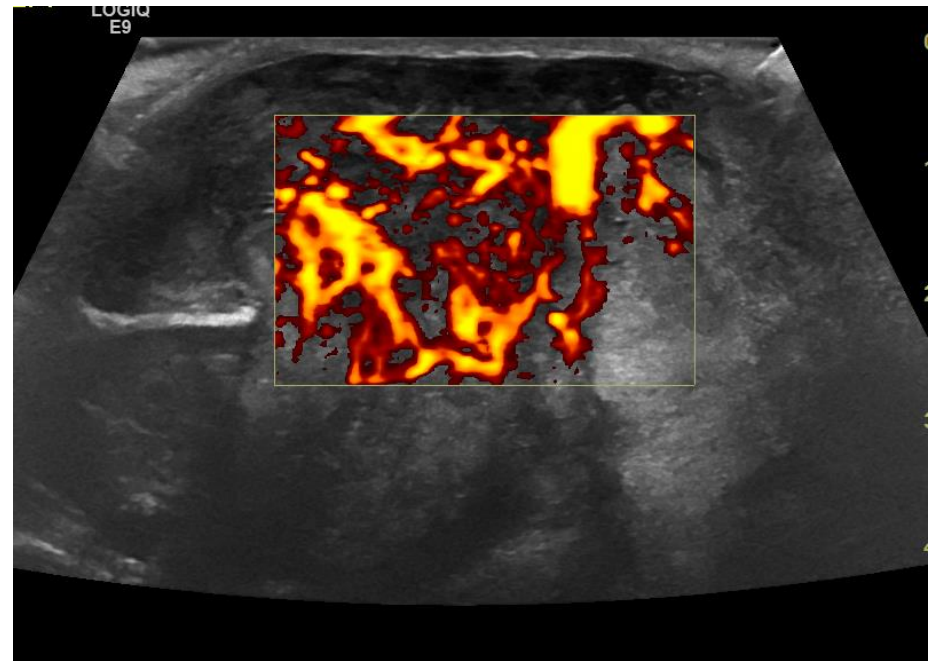
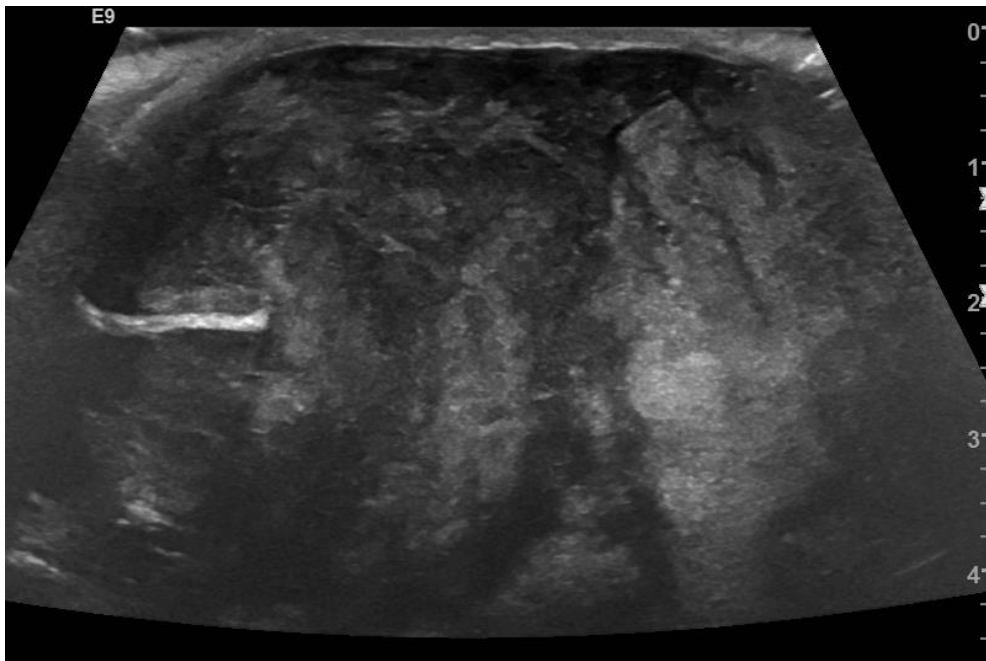
History:

52 yr M

Feeling of mass  
in foot







## Diagnosis – Telangiectatic osteosarcoma

Telangiectatic osteosarcoma is typically a purely lytic lesion with a permeative destructive growth pattern. This rapidly growing tumor often expands the contour of bone and shows features of cortical disruption with minimal or no periosteal new bone formation.

Remember even osteosarcomas can be lytic sometimes !