
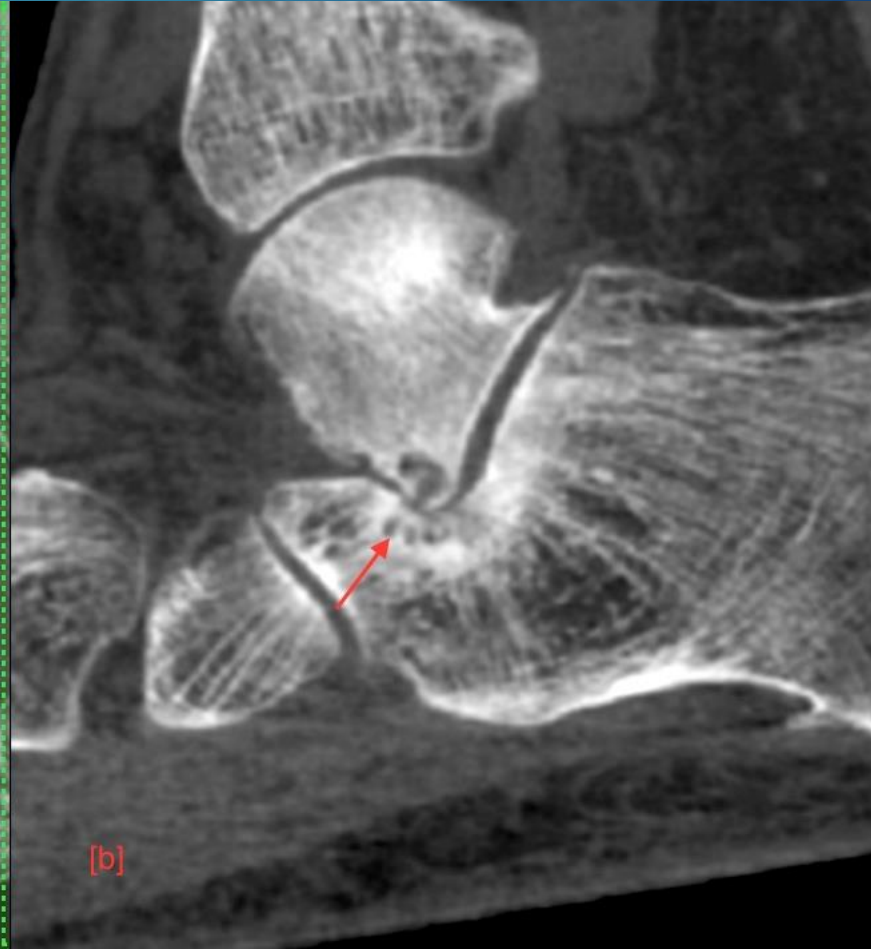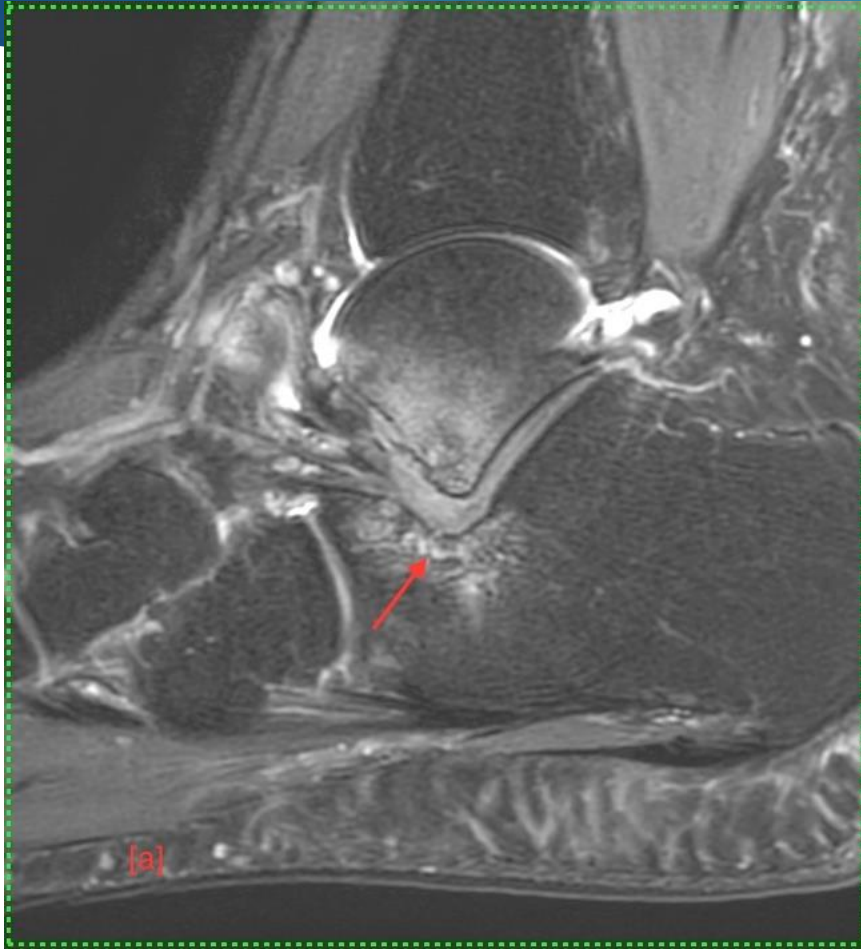


**MICOD 26/09/2023**  
**Case Courtesy: Dr. Khusbhoo Pilonia**





# Questions

- ▶ Q1. Name the modalities [a,b]
- ▶ Q2. Diagnosis



# Questions

- ▶ **A1. Name the modalities [a,b]**
  - ▶ a – MRI
  - ▶ b – Weightbearing CT
- ▶ **A2. Diagnosis**
- ▶ **Extraarticular talocalcaneal impingement**



# Extraarticular talocalcaneal impingement

- ▶ This is a biomechanical impingement usually seen in patients with flat foot deformity.
- ▶ The impingement is often overlooked on non weightbearing scans and the talocalcaneal apposition is best appreciated on weightbearing scans.
- ▶ Often misdiagnosed as sinus tarsi syndrome