


**MICOD 24/09/2023**

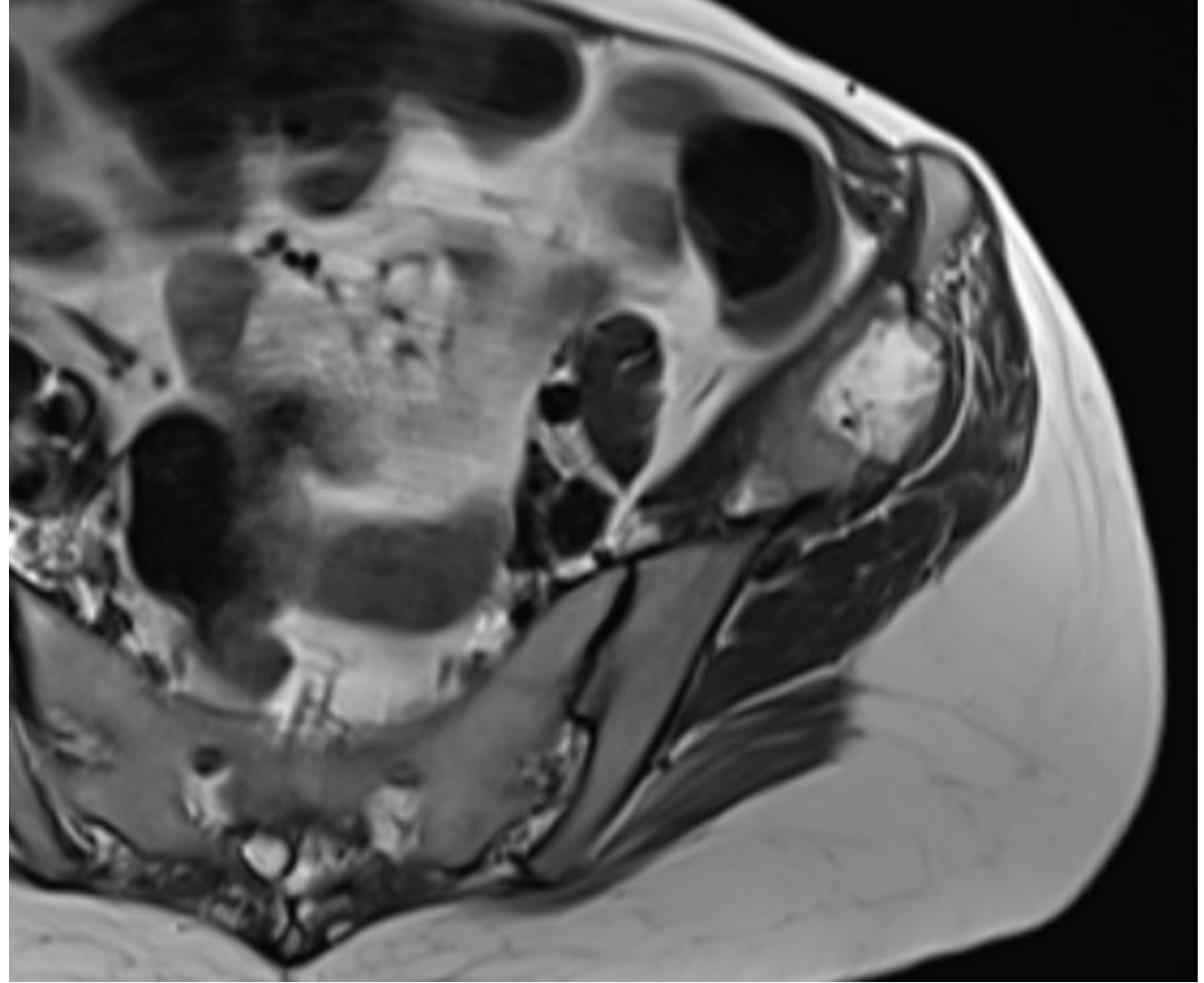
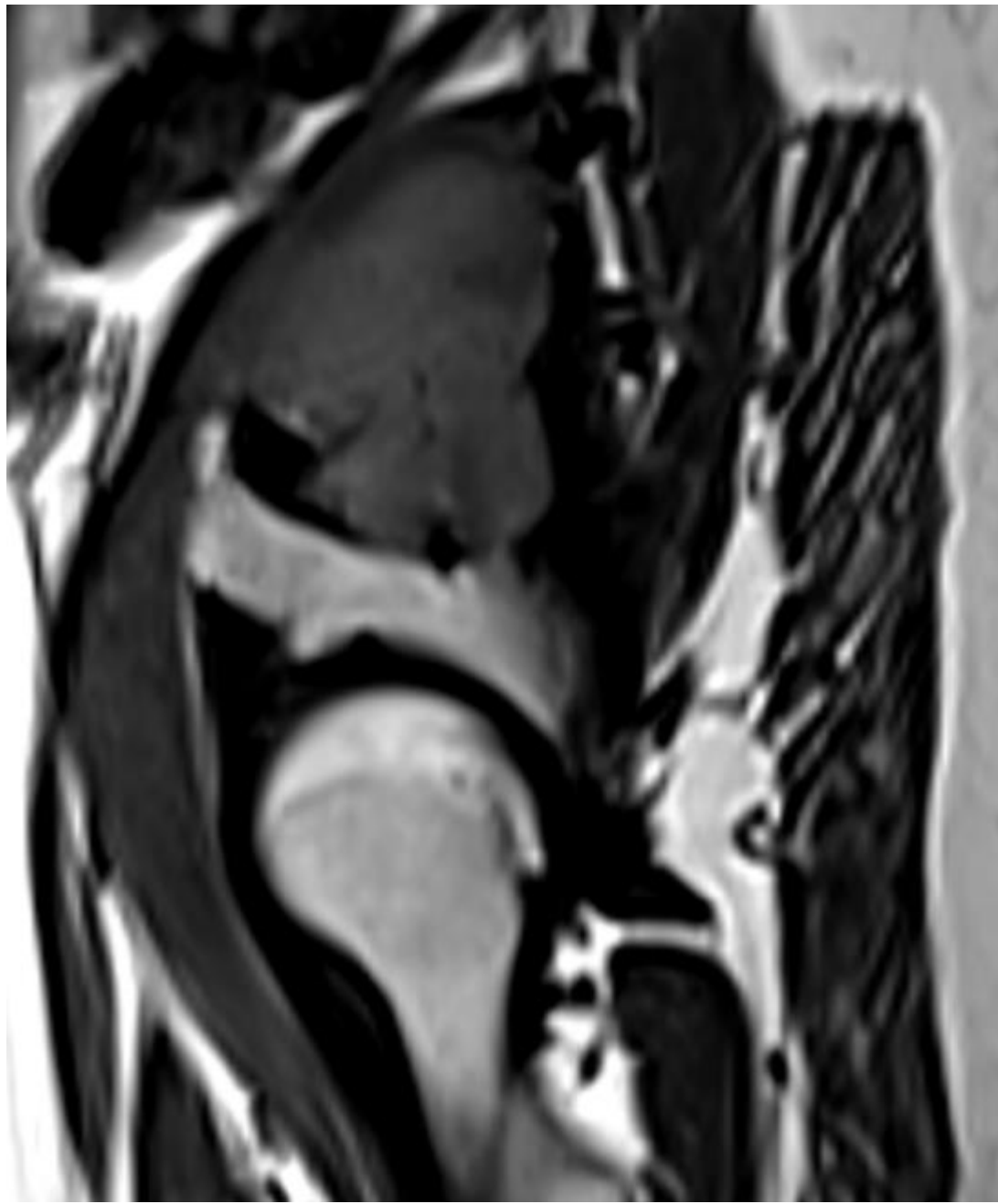
**Case Courtesy: Dr. Pushpa B. T (Ganga Hospital, Coimbatore)**

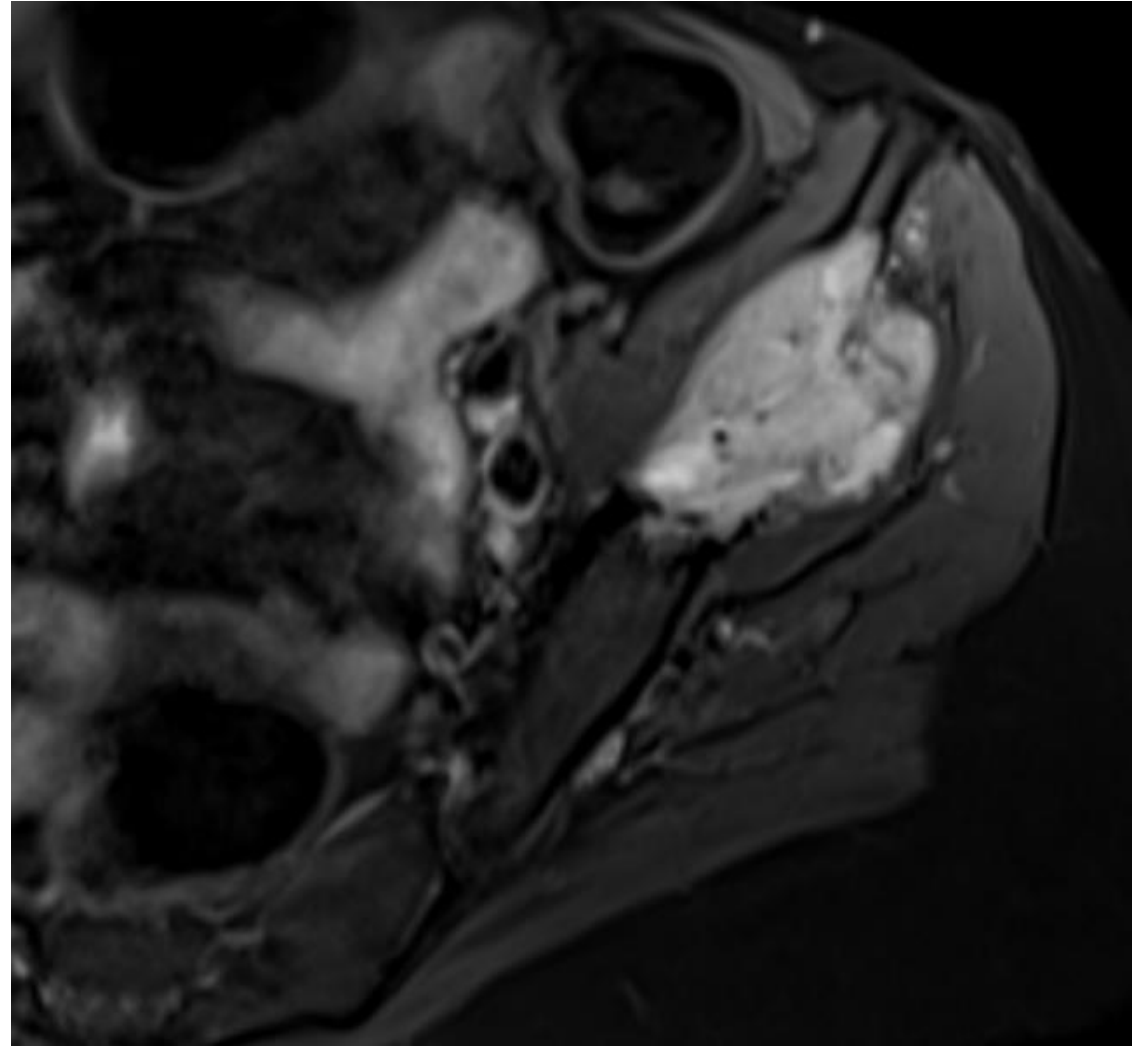
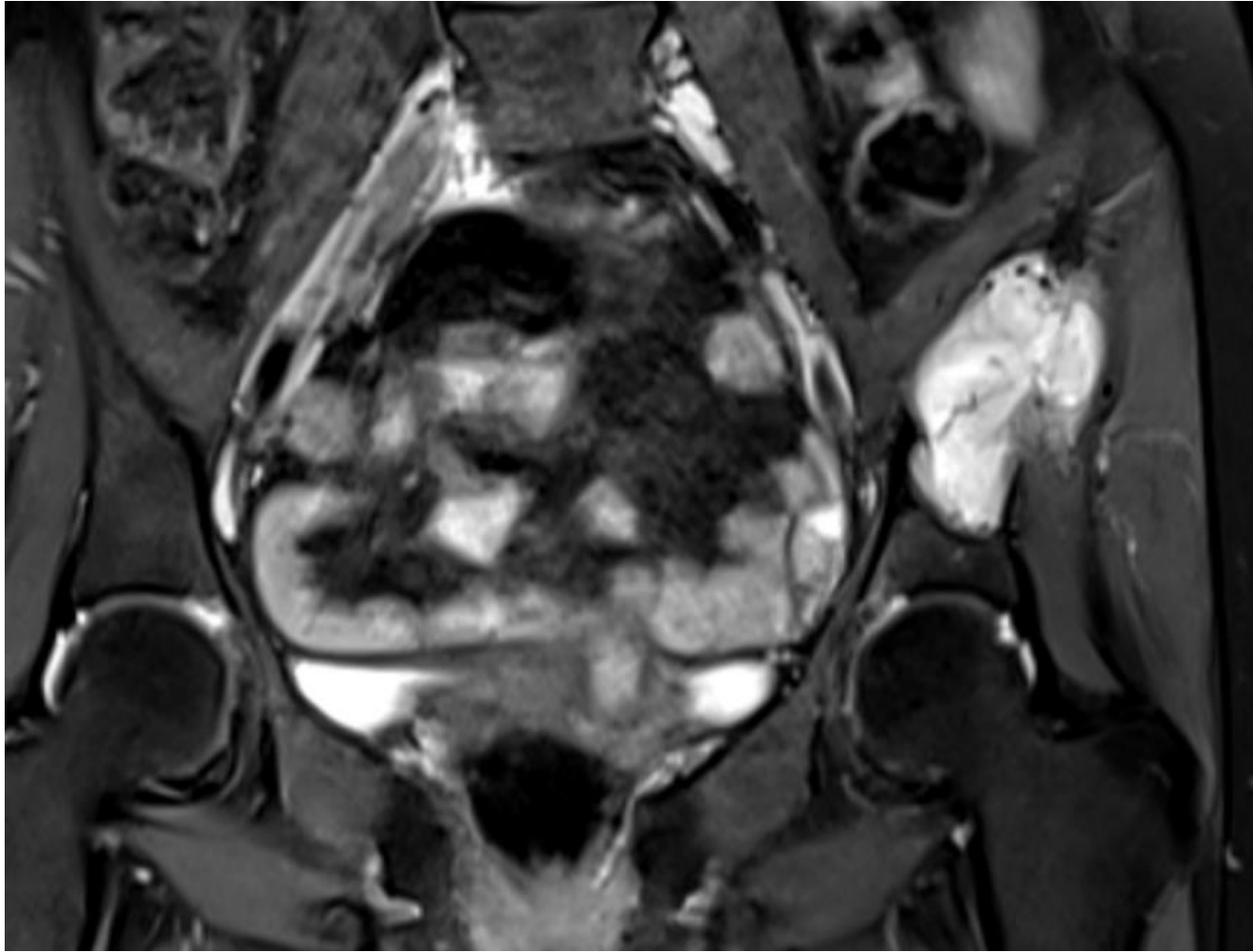


# Clinical History

- Know case of malignant systemic hypertension, hypoparathyroidism, dandy walker variant presenting with pain in the left side of pelvis.

In view of the above findings, the patient was subjected to MRI of abdomen and pelvis.







- **Biopsy - extra adrenal pheocromocytoma**
- Salt and pepper appearance of bone tumor

