

MICOD – 23/09/2023

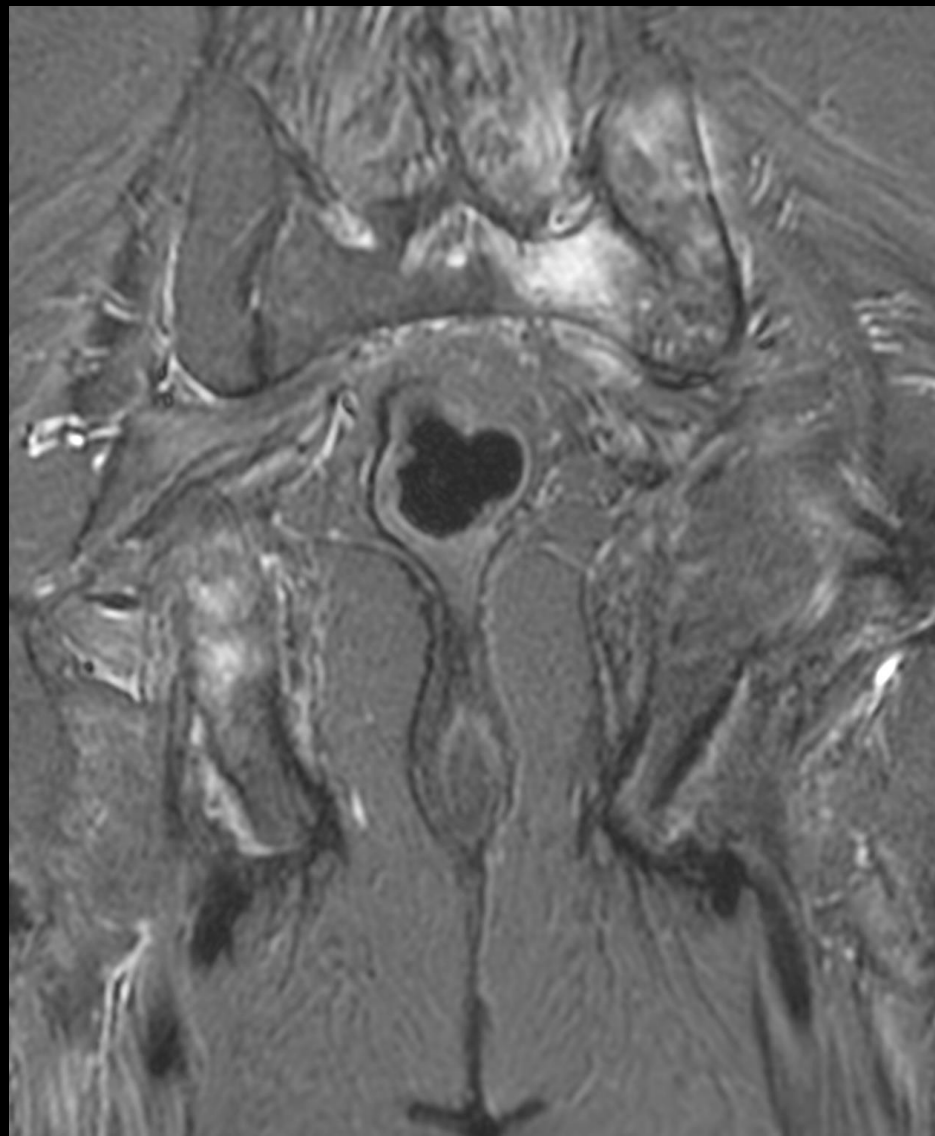
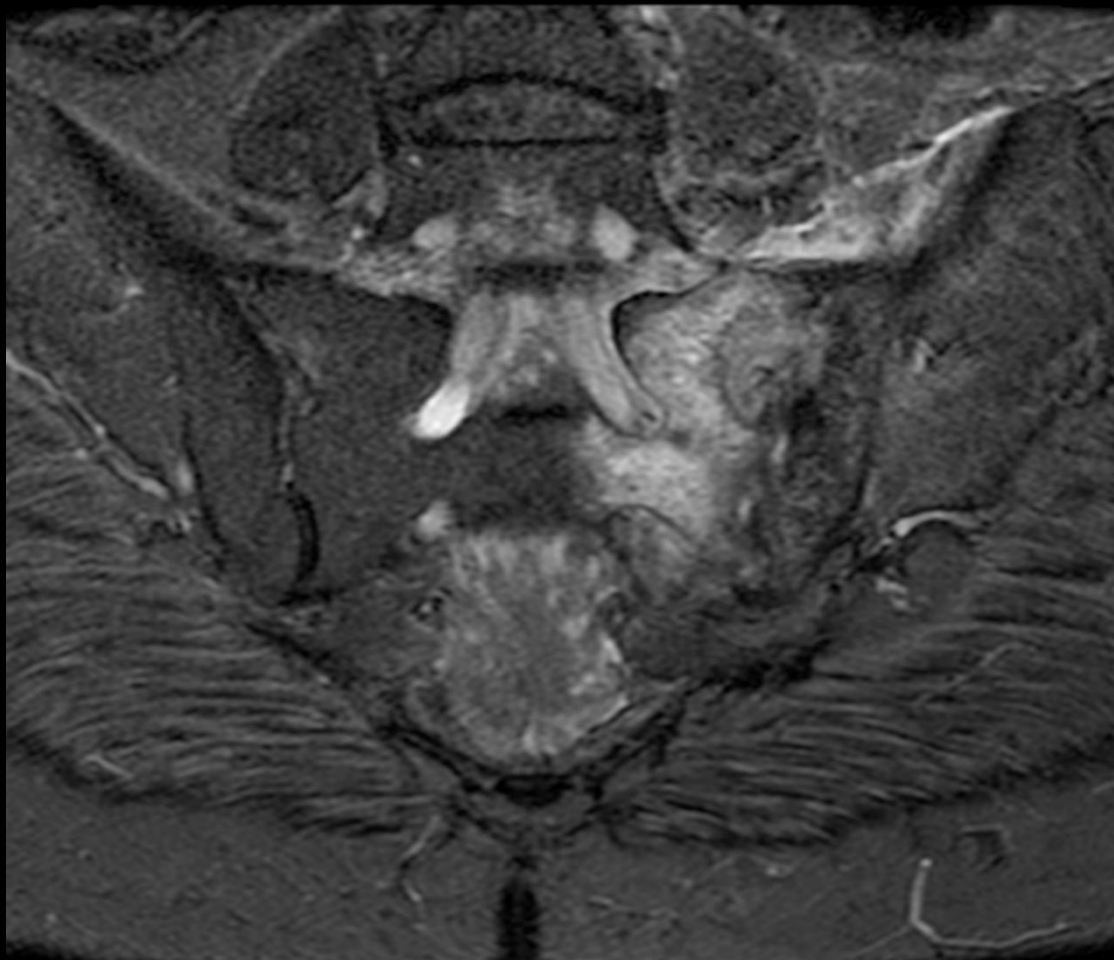
Case contributor – Dr. Chinmay P. Mehta

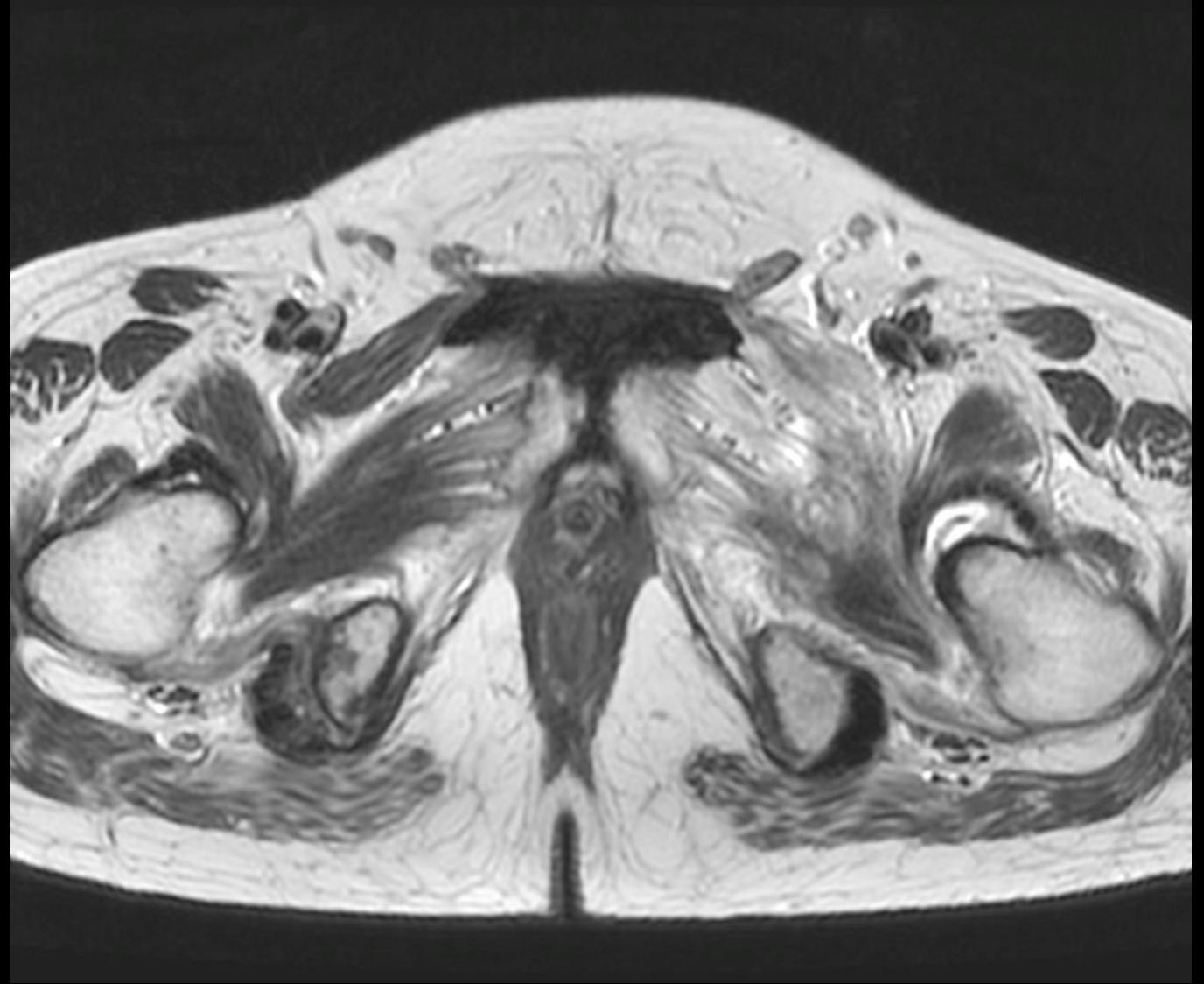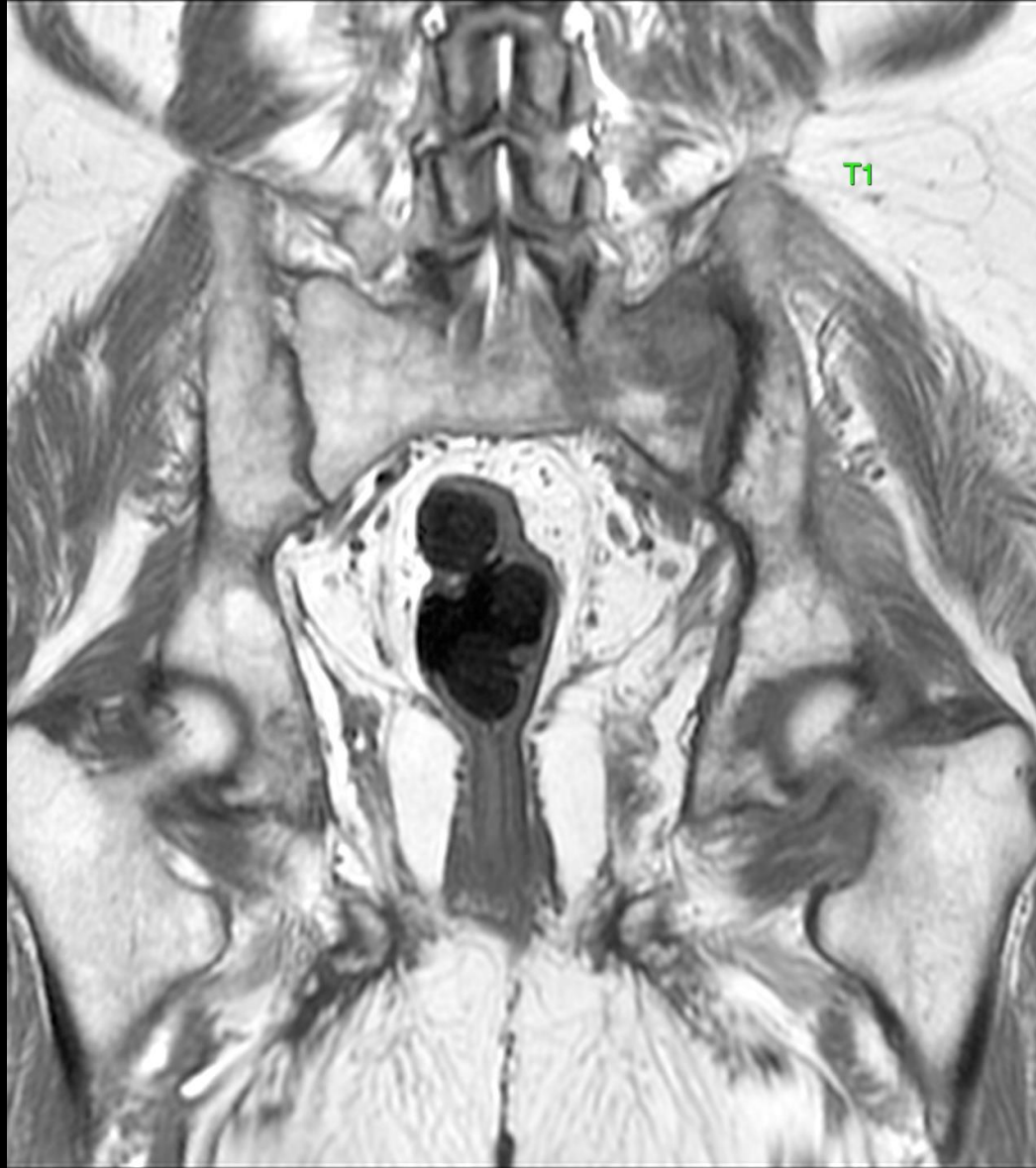MI-COD

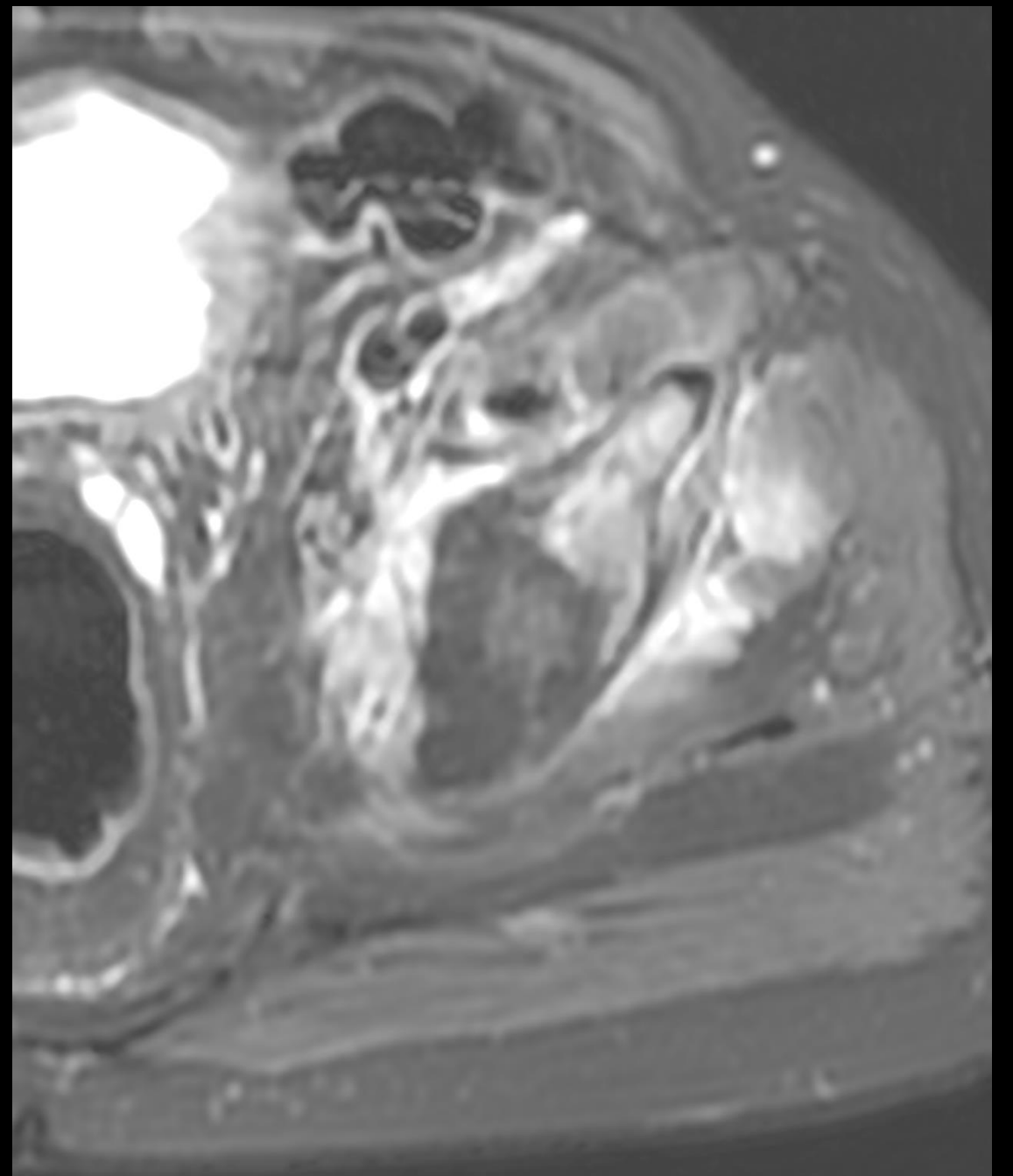
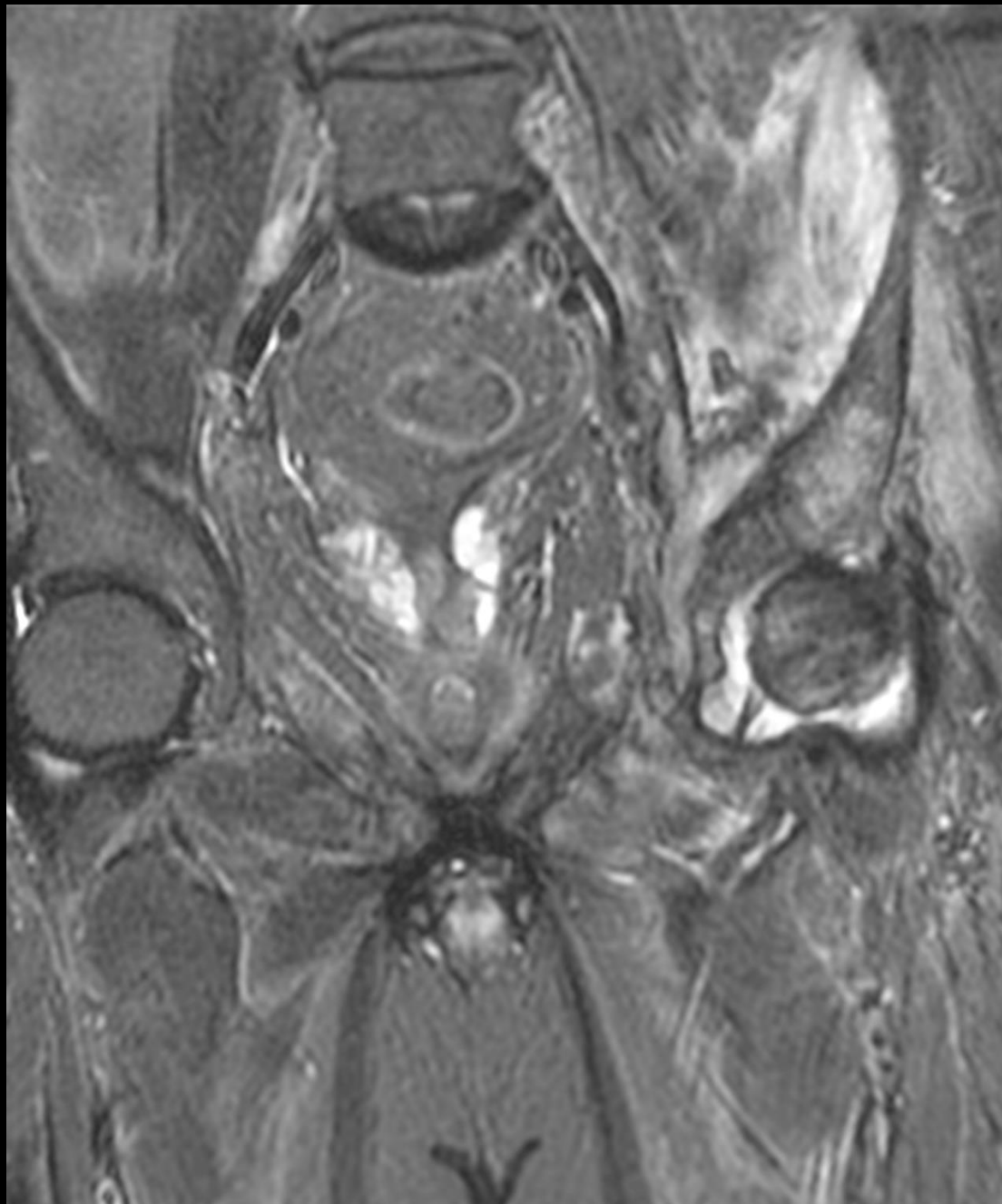
MSS INDIA- Case Of the Day



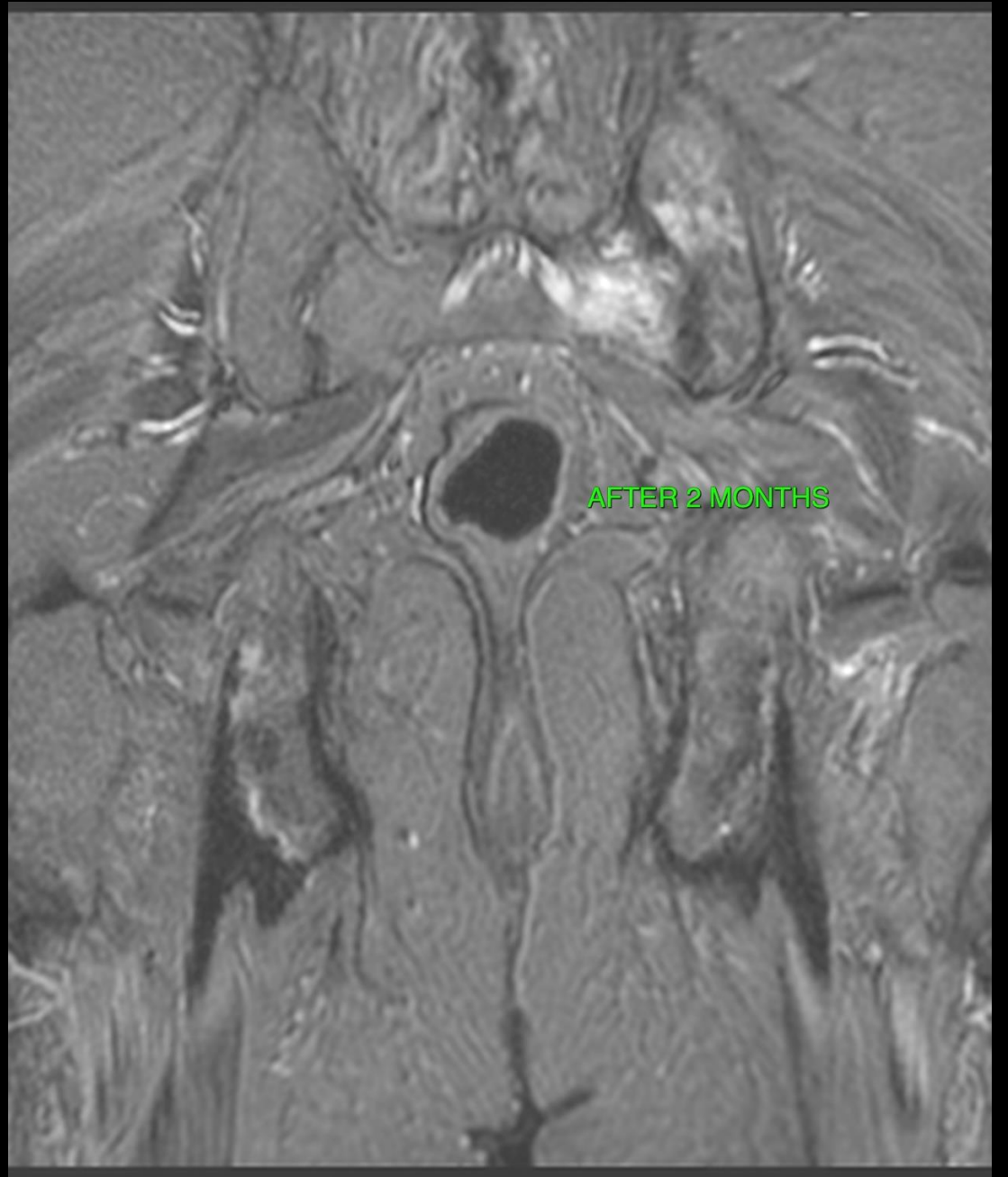
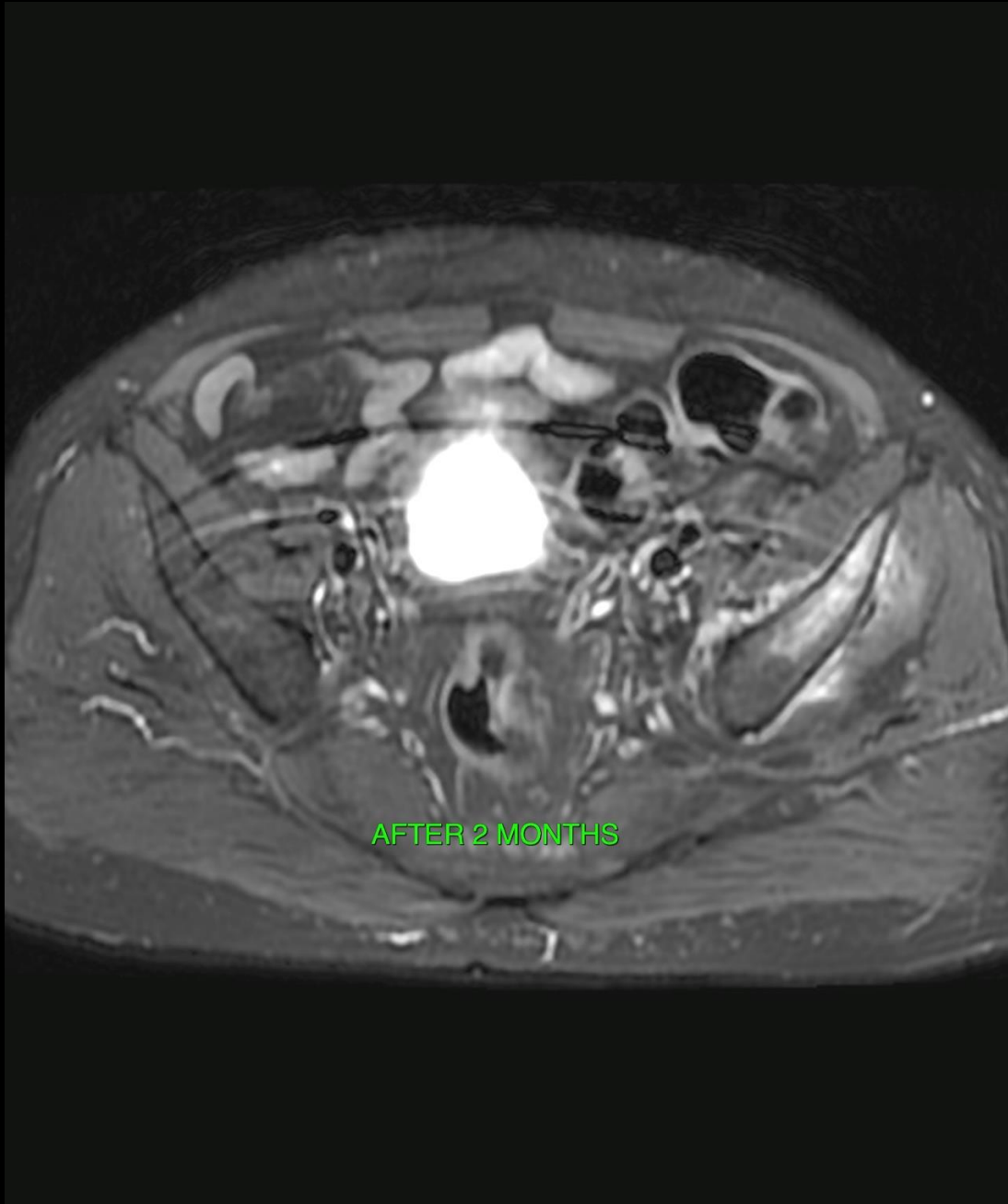
63 yr. old hypertensive and diabetic patient
with left hip pain.

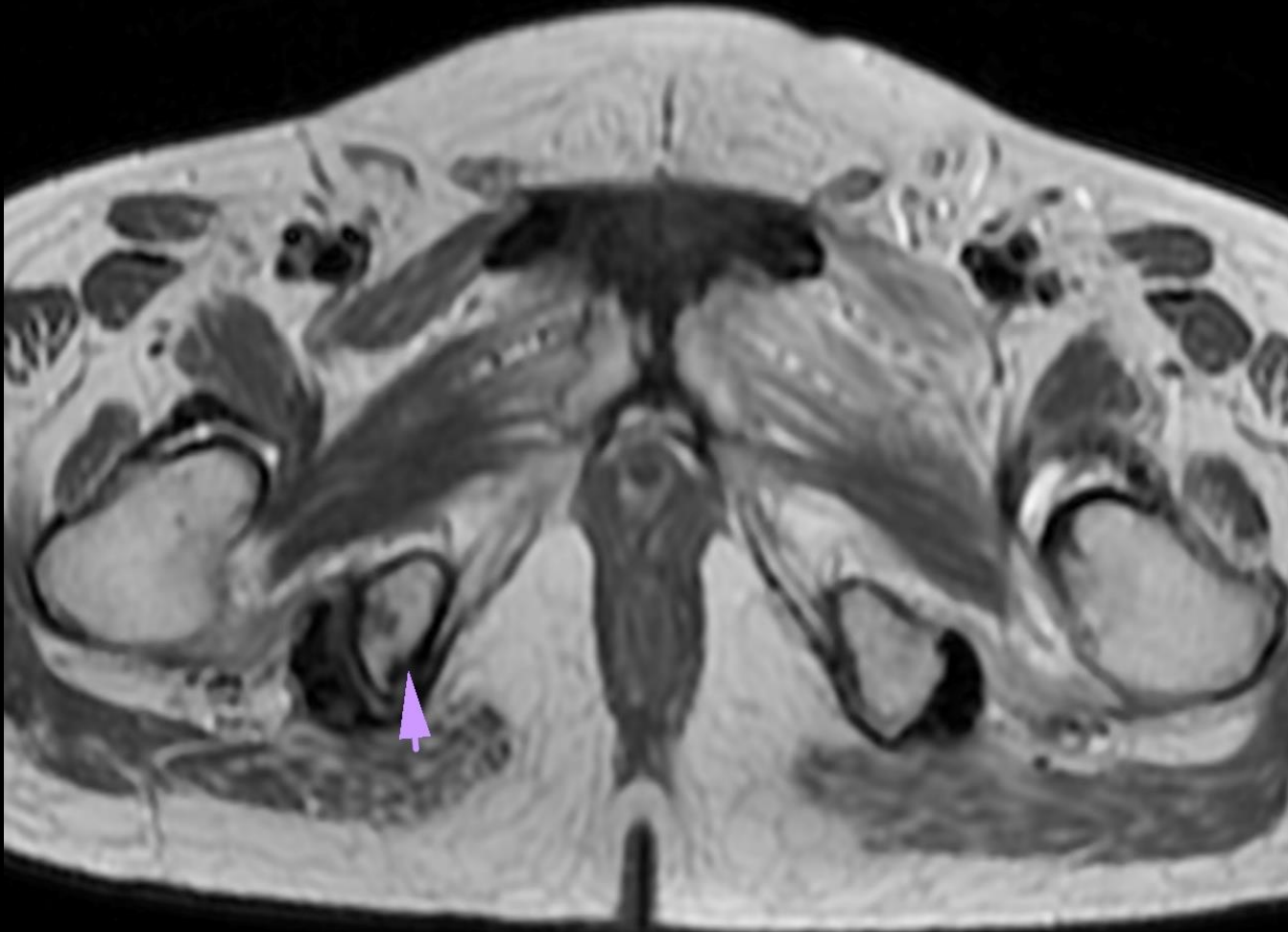
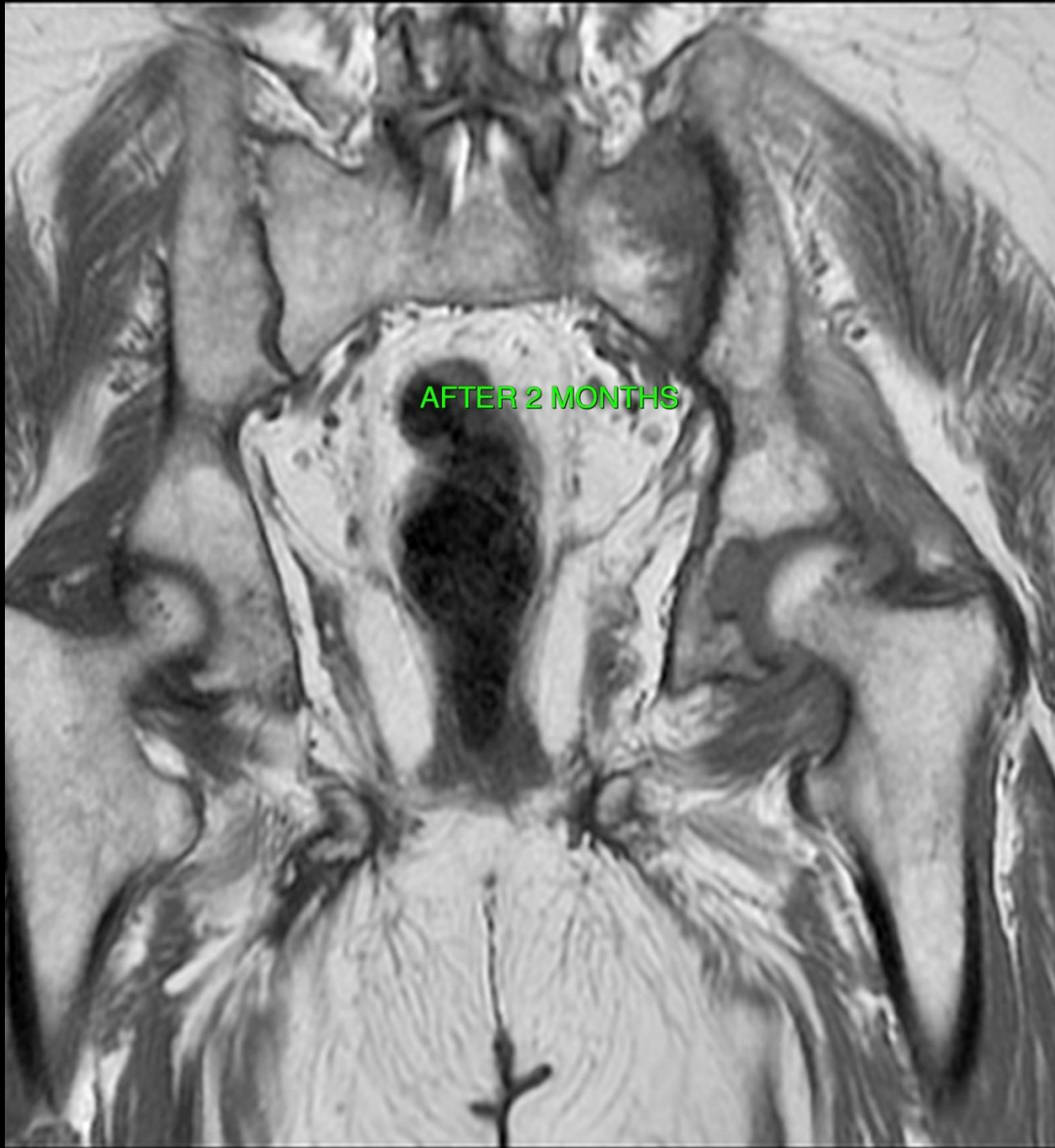





1. What is the likely etiology ?
 - a. Inflammatory
 - b. Infective
 - c. Neoplastic
 - d. Loser's zones.
2. Next step ?
 - a. Look up the infective and tumor markers
 - b. Biopsy and microbiological and histopathology analysis
 - c. Both of the above.
 - d. Dexa for osteoporosis.
3. If biopsy was performed, what are tests one should order ?





1. What is the likely etiology ?

a. Inflammatory

b. **Infective**

c. Neoplastic

d. Loser's zones.

2. Next step ?

a. Look up the infective and tumor markers

b. Biopsy and microbiological and histopathology analysis

c. **Both of the above.**

d. Dexa for osteoporosis.

3. If biopsy was performed, what are tests one should order ?

A): HPR, Gene expert, Routine, Tb and Fungal cultures.

TAKE HOME MESSAGE:

1. All multifocal lesions are not neoplasms and neither all are tubercular.

2. Always submit sample for fungal cultures along with the rest even if the lesion looks like a neoplasm. Surprises never come with a forewarning.

AFST- BROTH MICRO DILUTION

<u>Test</u>	<u>Result</u>
AFST- BROTH MICRO DILUTION SPECIMEN	CT GUIDED BIOPSY OF LEFT SACRO-ILIAC JOINT
FUNGAL ISOLATE	ASPERGILLUS FUMIGATUS
Anidulafungin	* <=0.0313 mcg/ml
Micafungin	* <=0.0313 mcg/ml
Caspofungin	Susceptible (<=0.0313) mcg/ml
5-Flucytosine	* >=16.0 mcg/ml
Posaconazole	* <=0.0313 mcg/ml
Voriconazole	Susceptible (0.0625) mcg/ml
Fluconazole	* >=16.0 mcg/ml
Amphotericin B	Susceptible (0.50) mcg/ml