
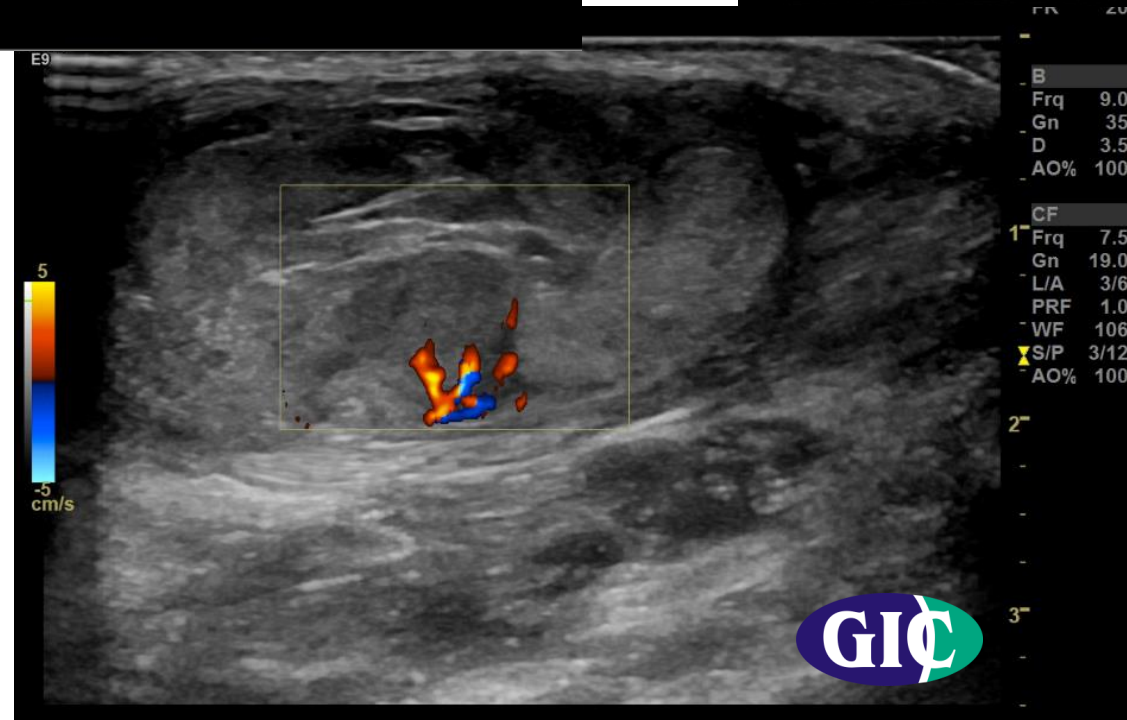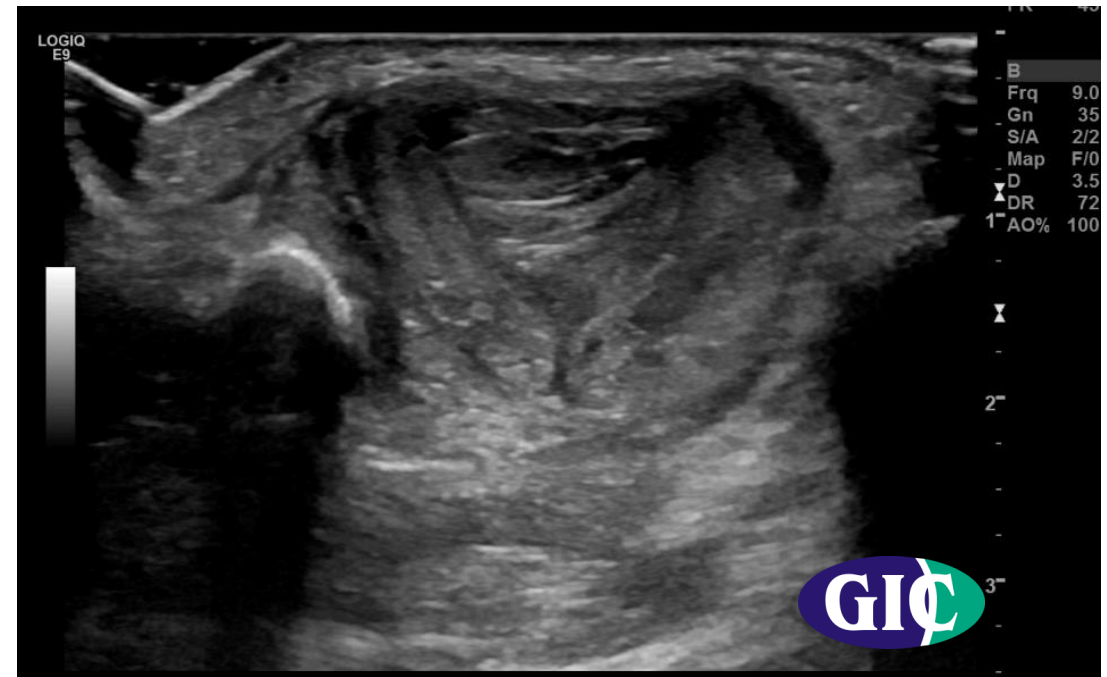
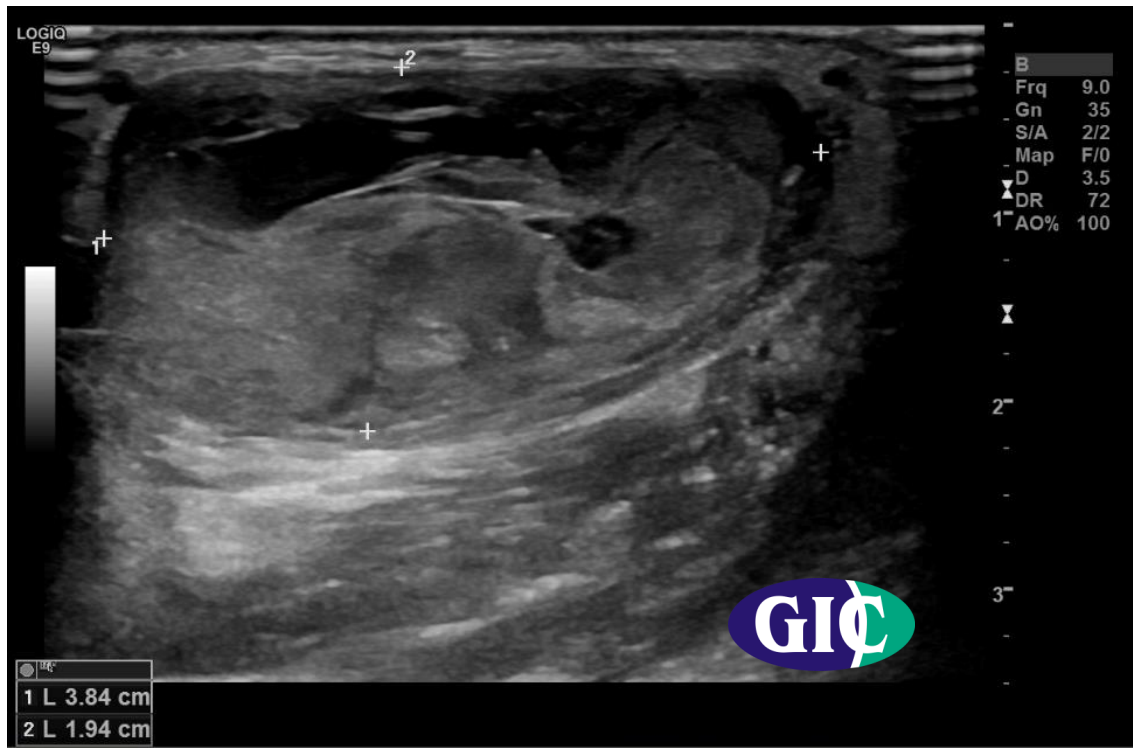


MICOD 22/09/2023
Case Courtesy: Dr. Drushi Patel

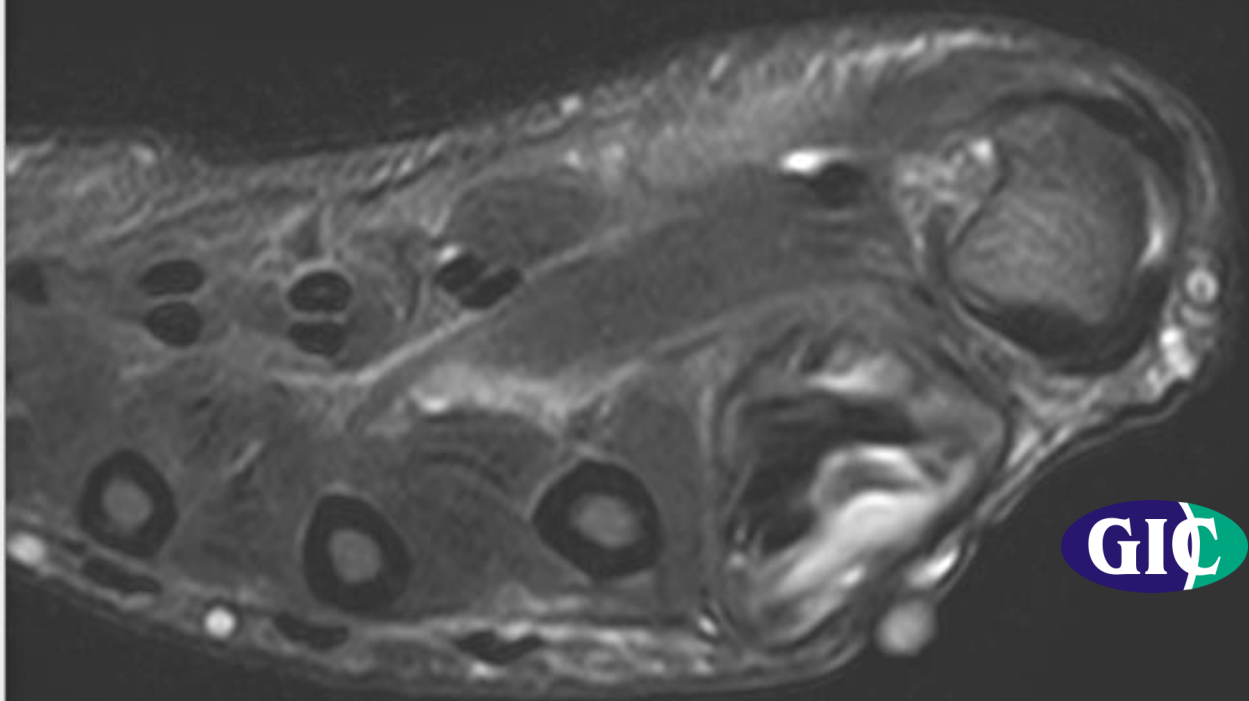


Clinical presentation

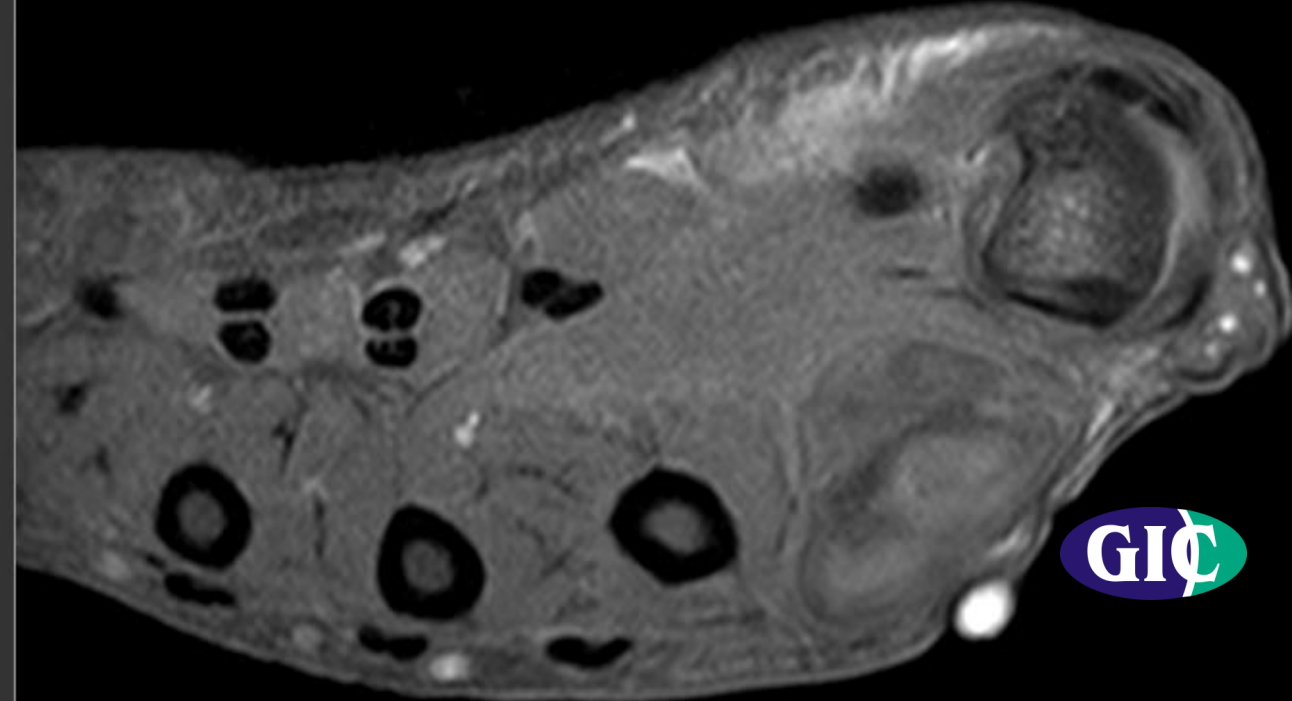
- 62 year old male presented with firm swelling in 1st web space and associated mild pain.
- No H/o Trauma, Major illness, Tb , weigh loss or surgery

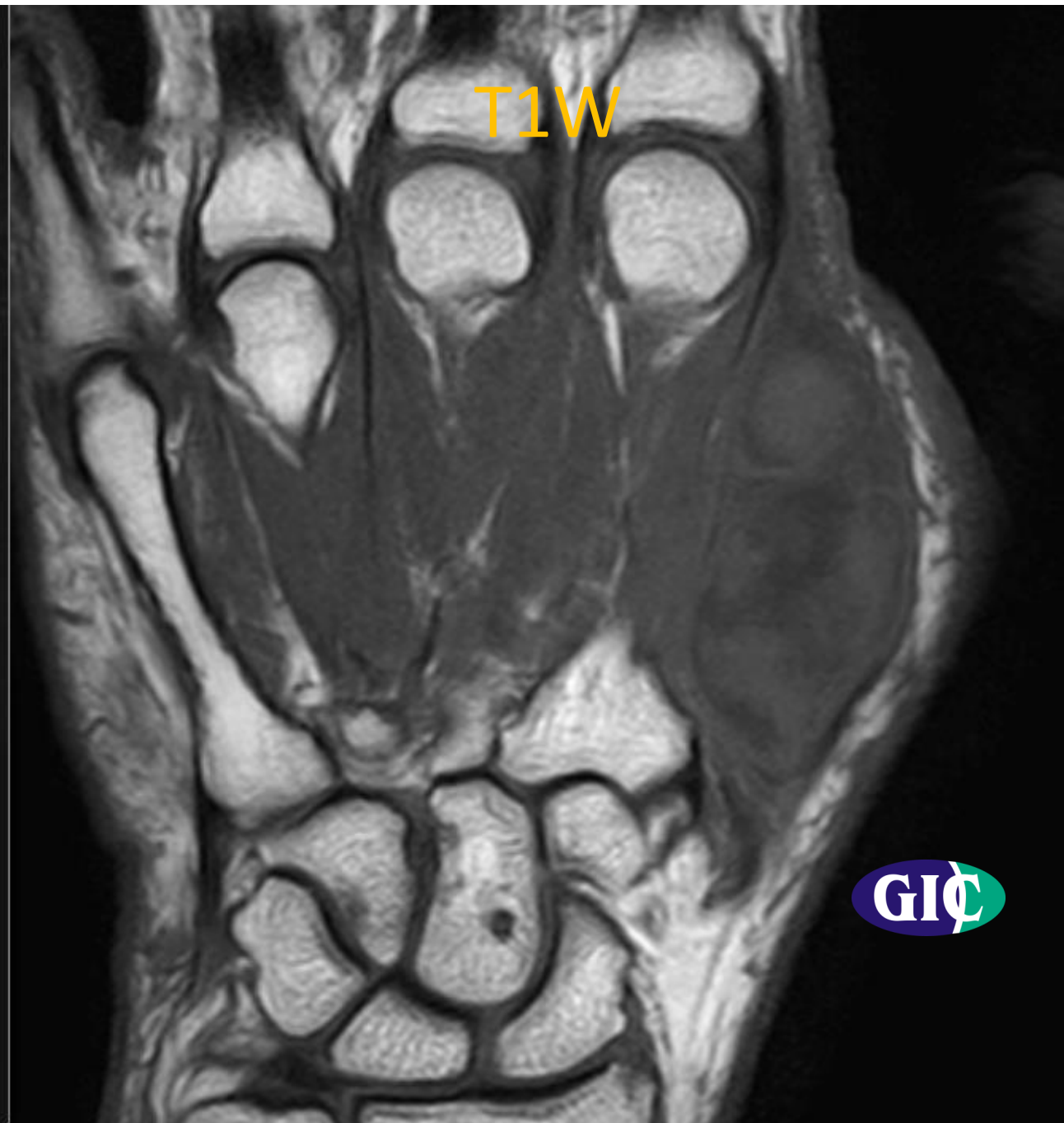
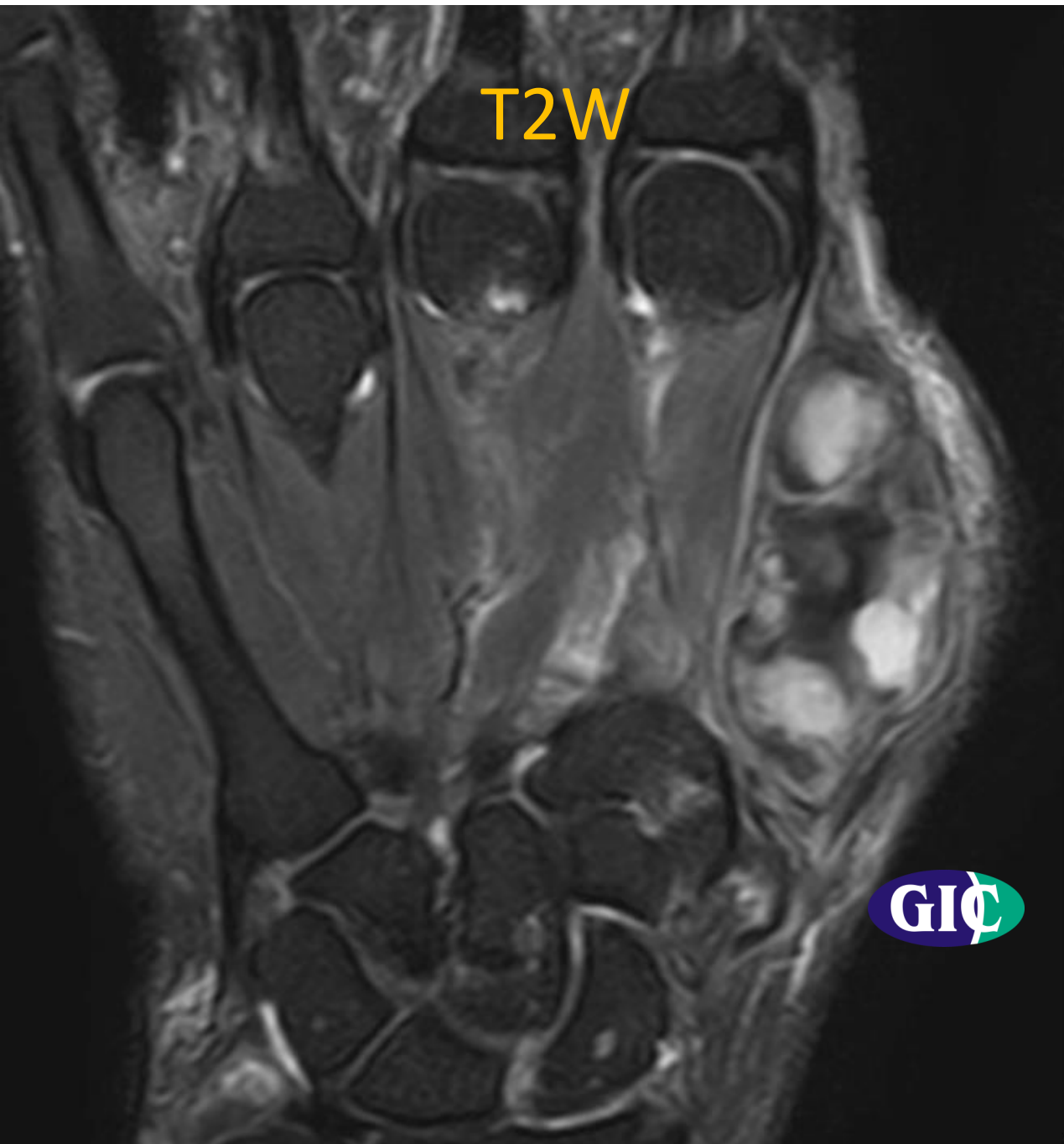

T2W

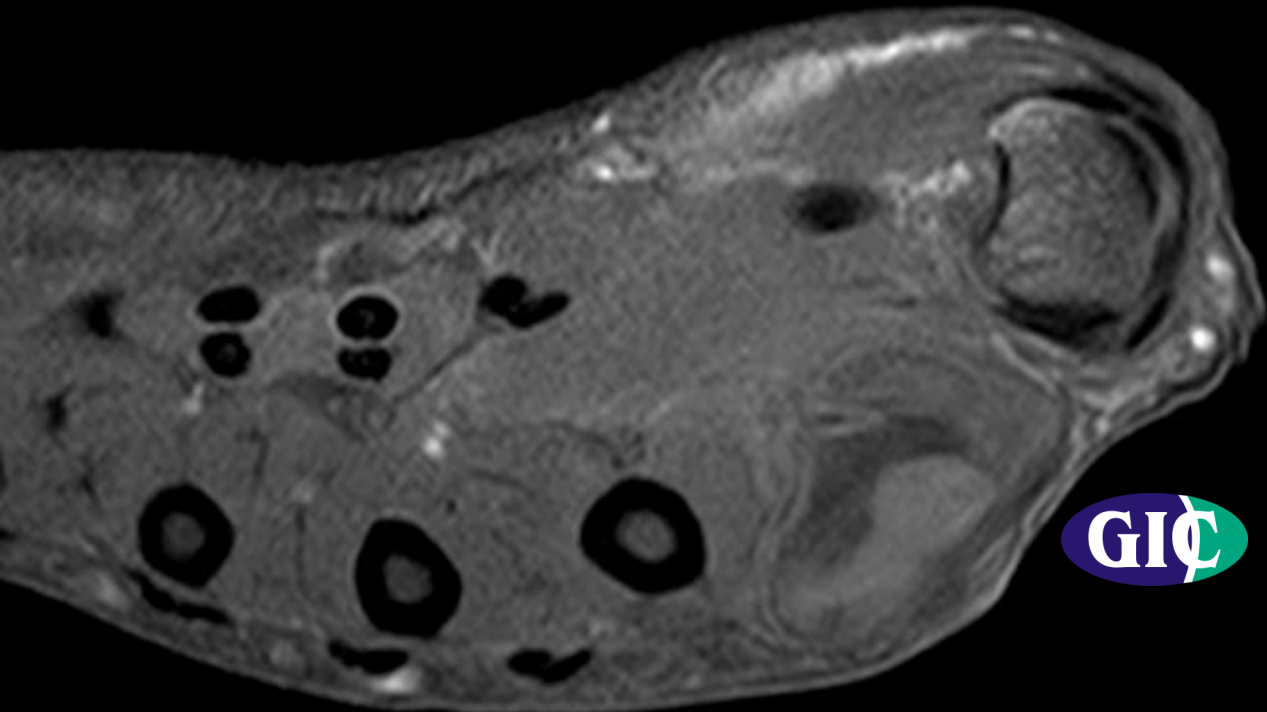


T1W



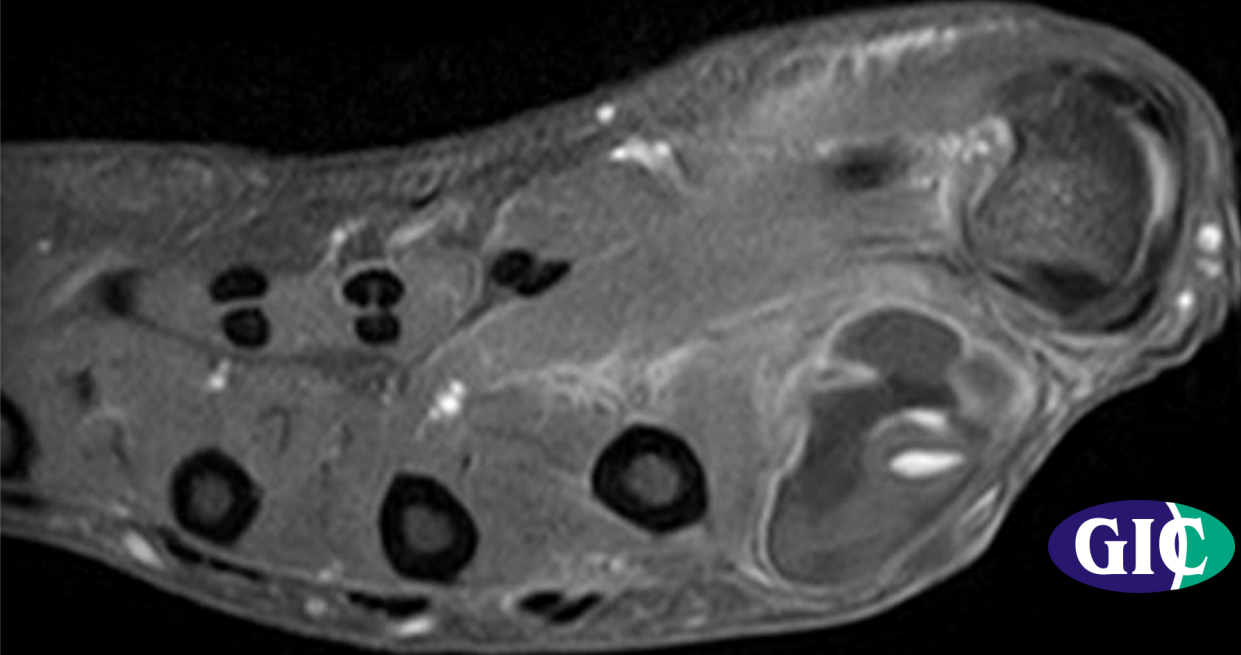


Pre contrast



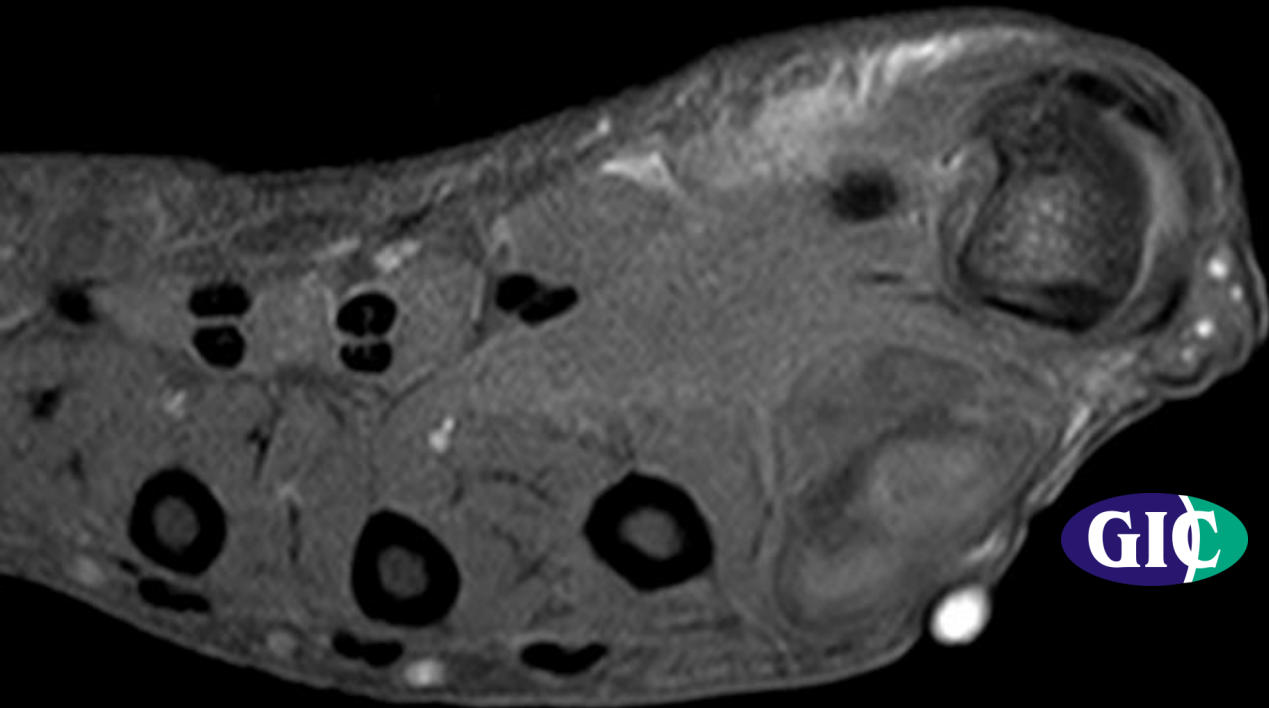
GIÇ

Post contrast

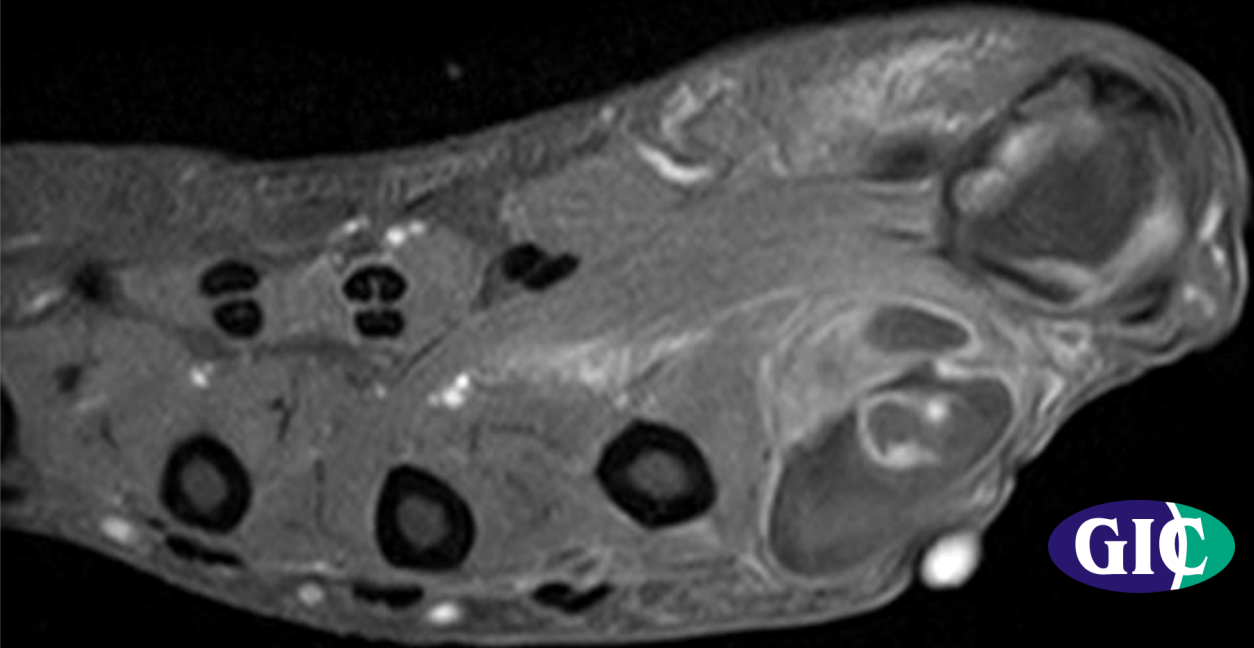


GIÇ

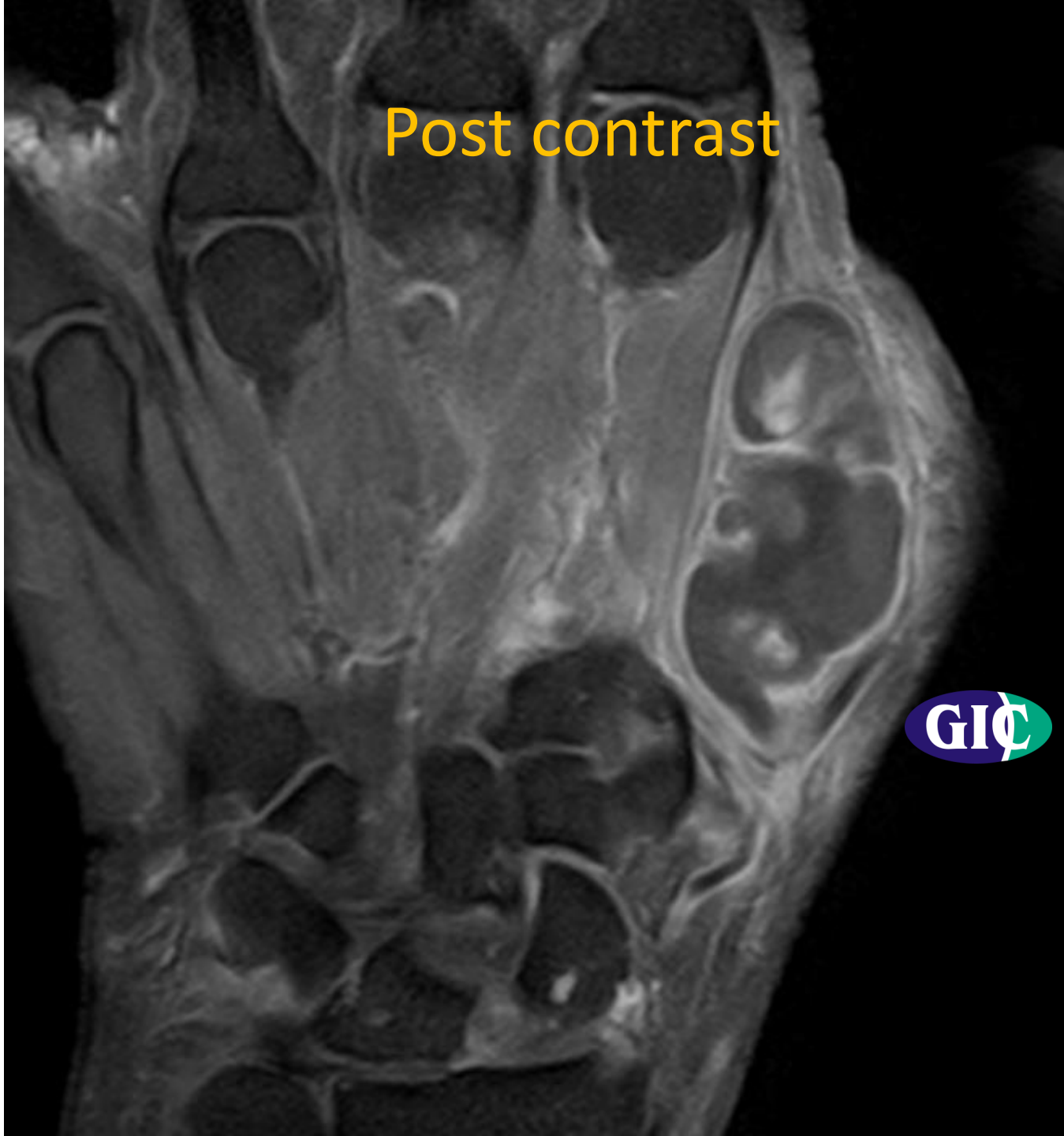Pre contrast



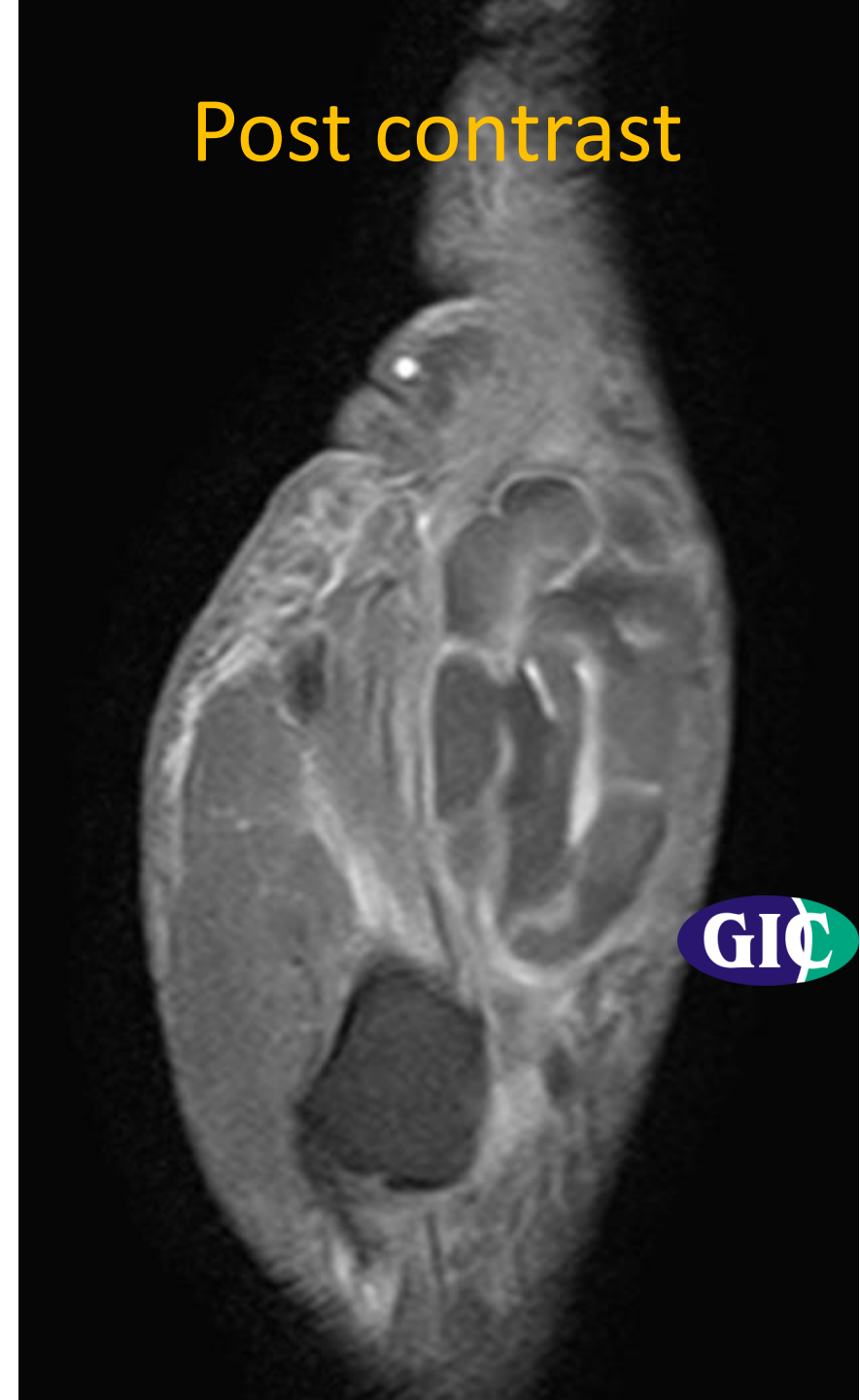
Post contrast



Post contrast



Post contrast



Pre- biopsy investigations : INR Raised

Diagnosed with
Von Willebrand Factor deficiency (Coagulation disorder)

Final Diagnosis : Organised Hematoma

Resolved spontaneously on follow up clinical evaluation