

Date: 20.09.2023

Case Courtesy: Dr. Drushi Patel



# MI-COD

MSS INDIA- Case Of the Day





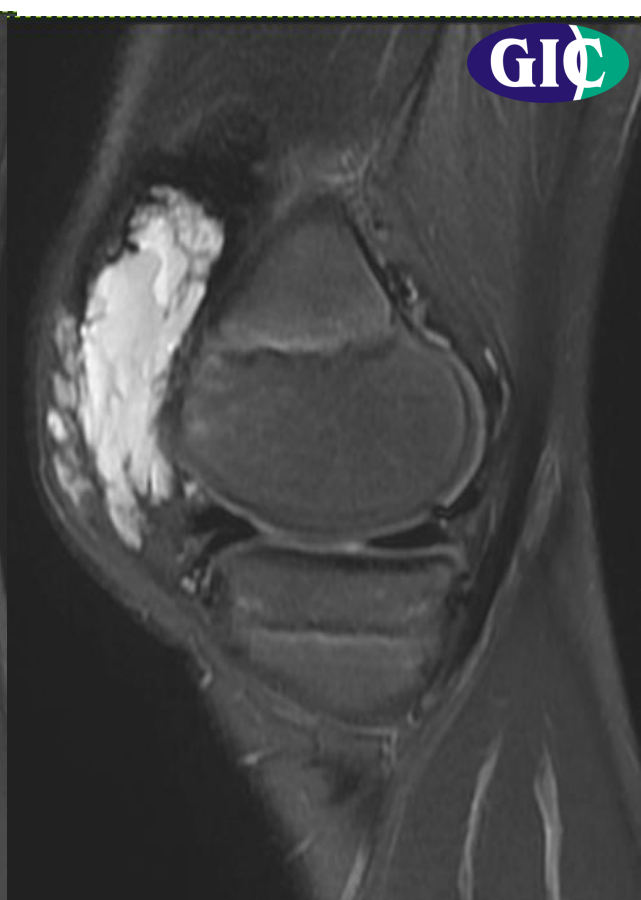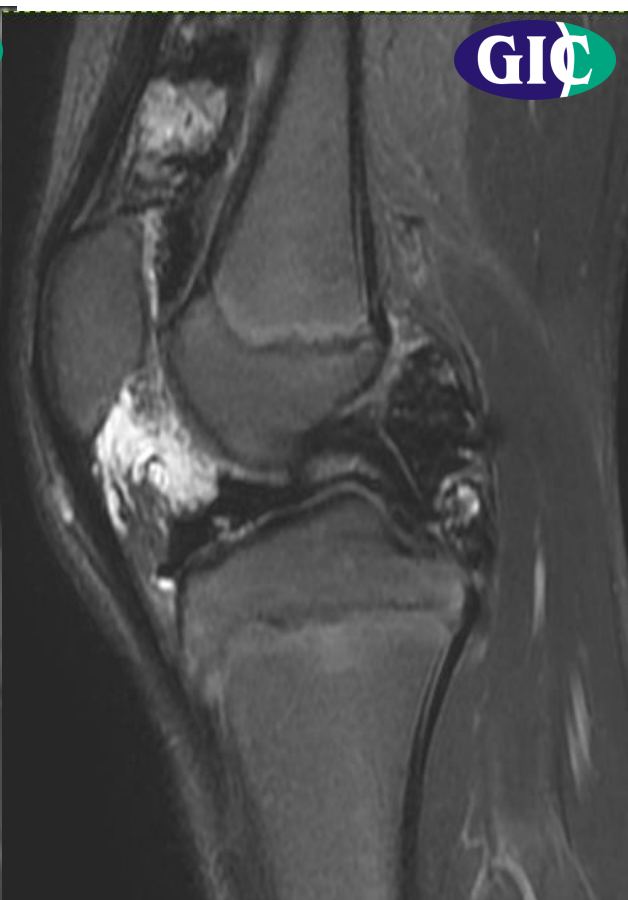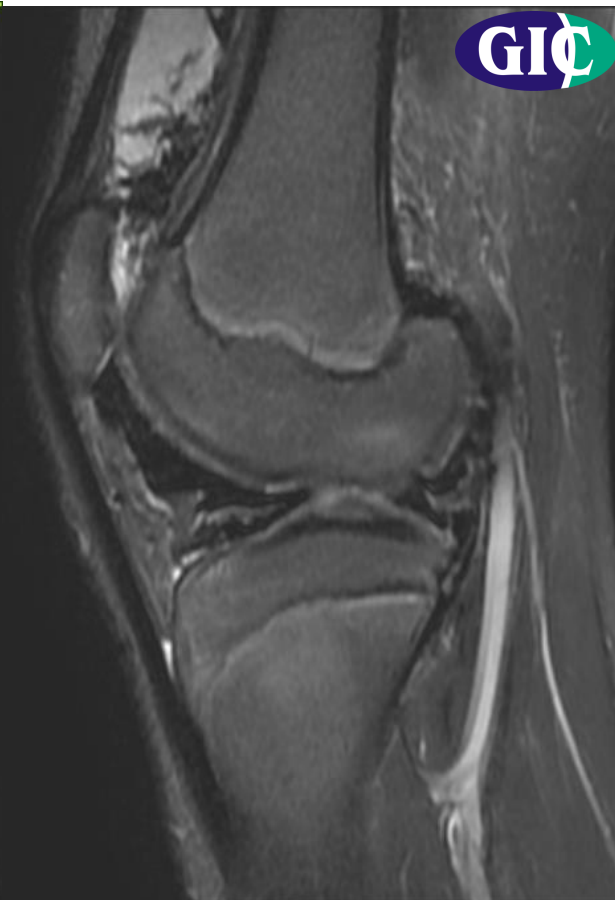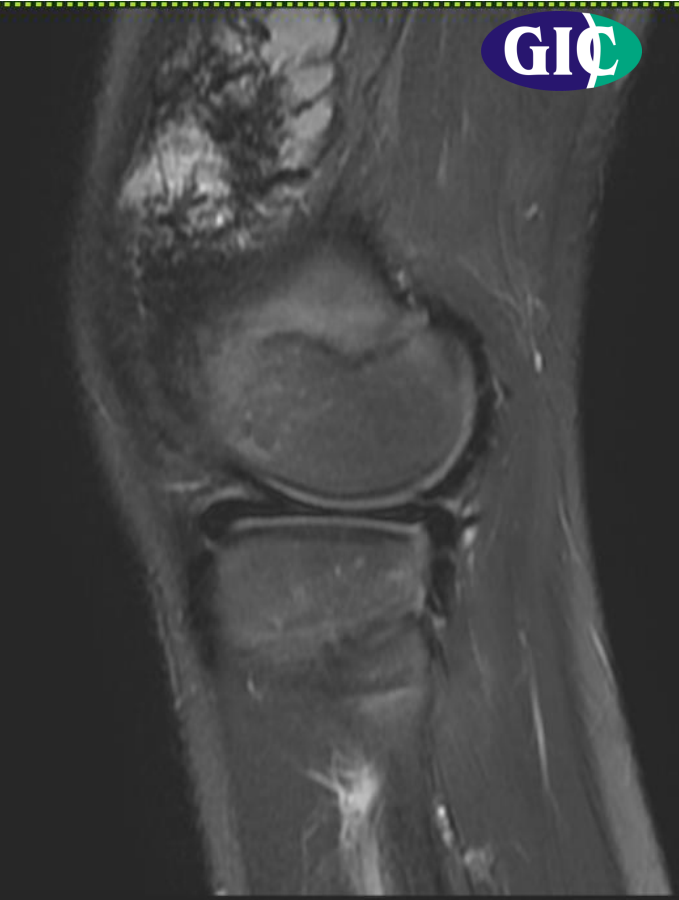# MICOD

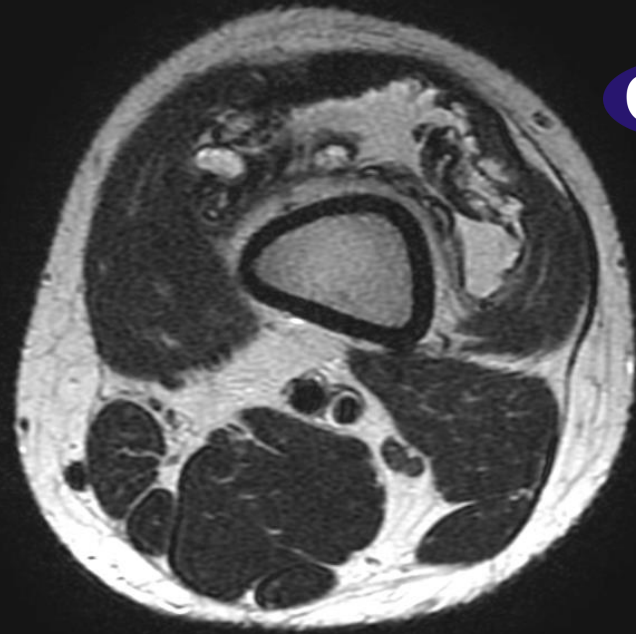
Dr. Drushi Patel

# Clinical presentation

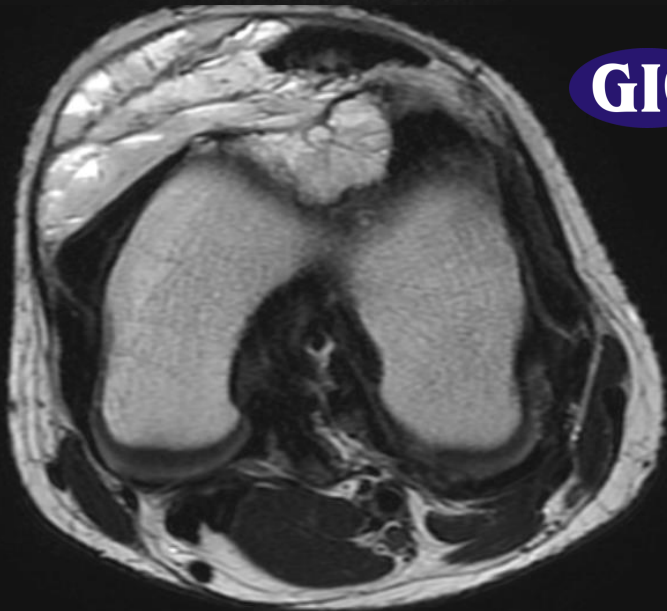
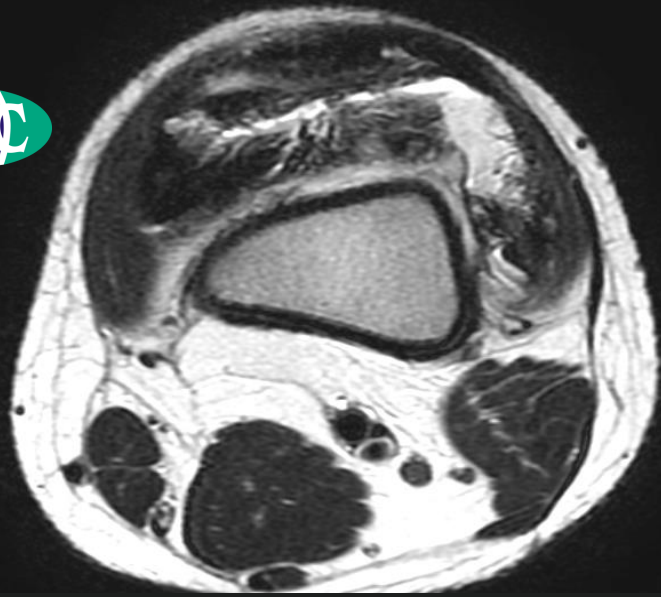
12 year old football player noticed knee pain and swelling  
since a week



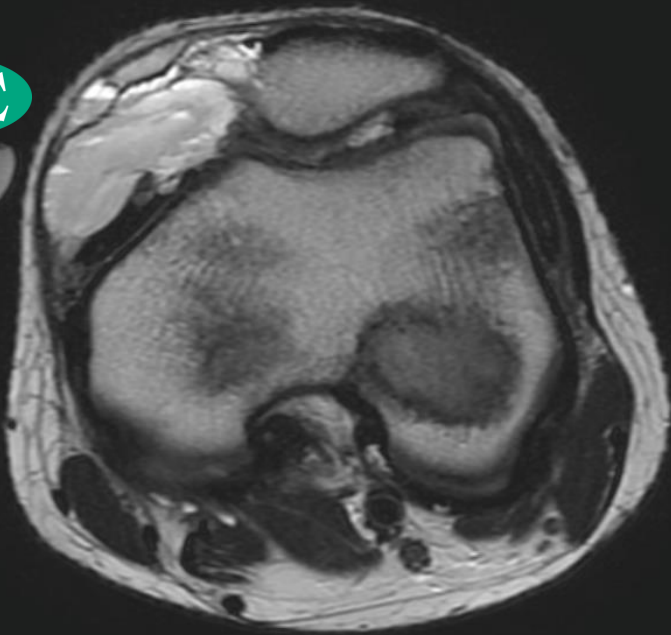


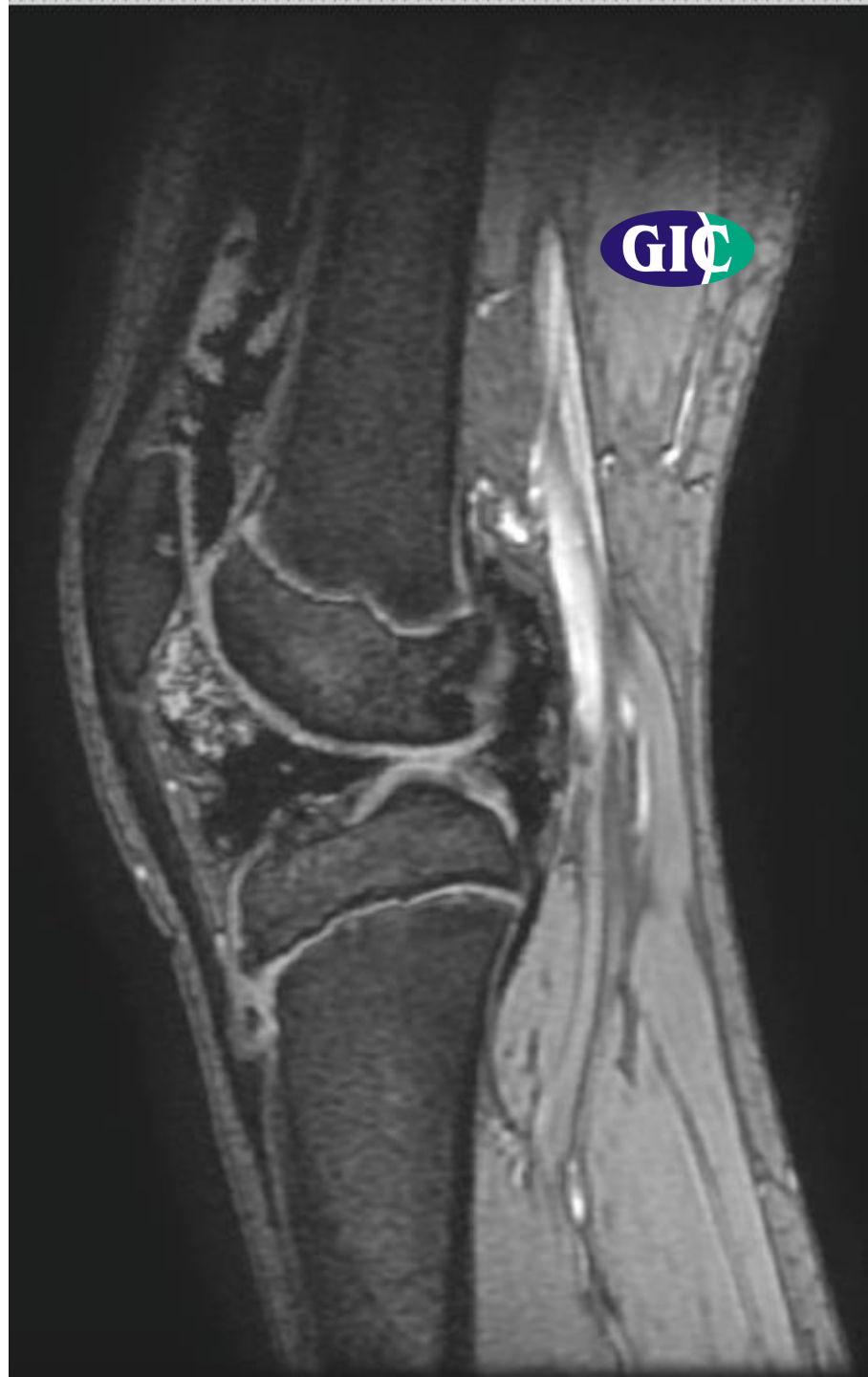

GIC

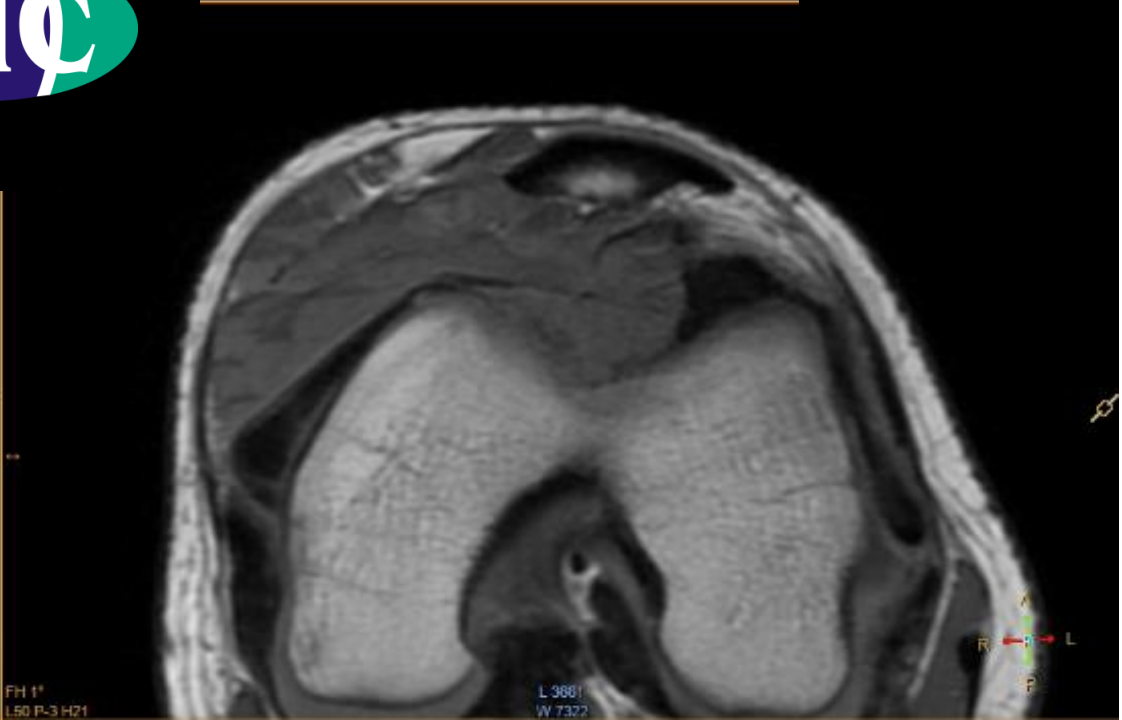
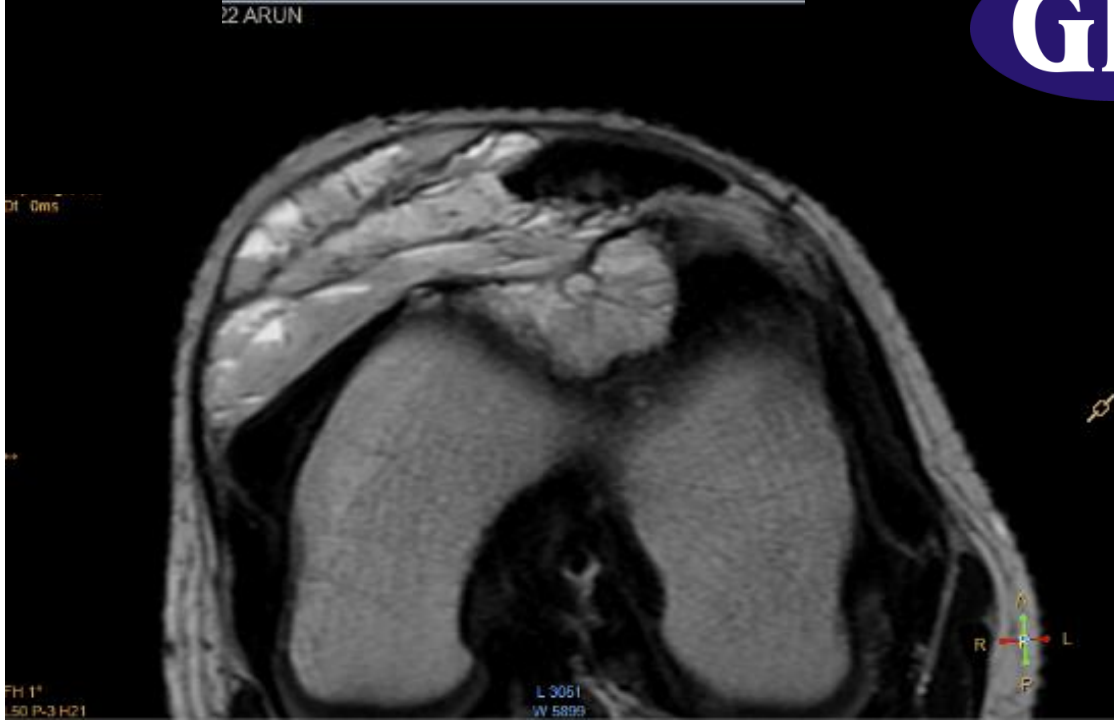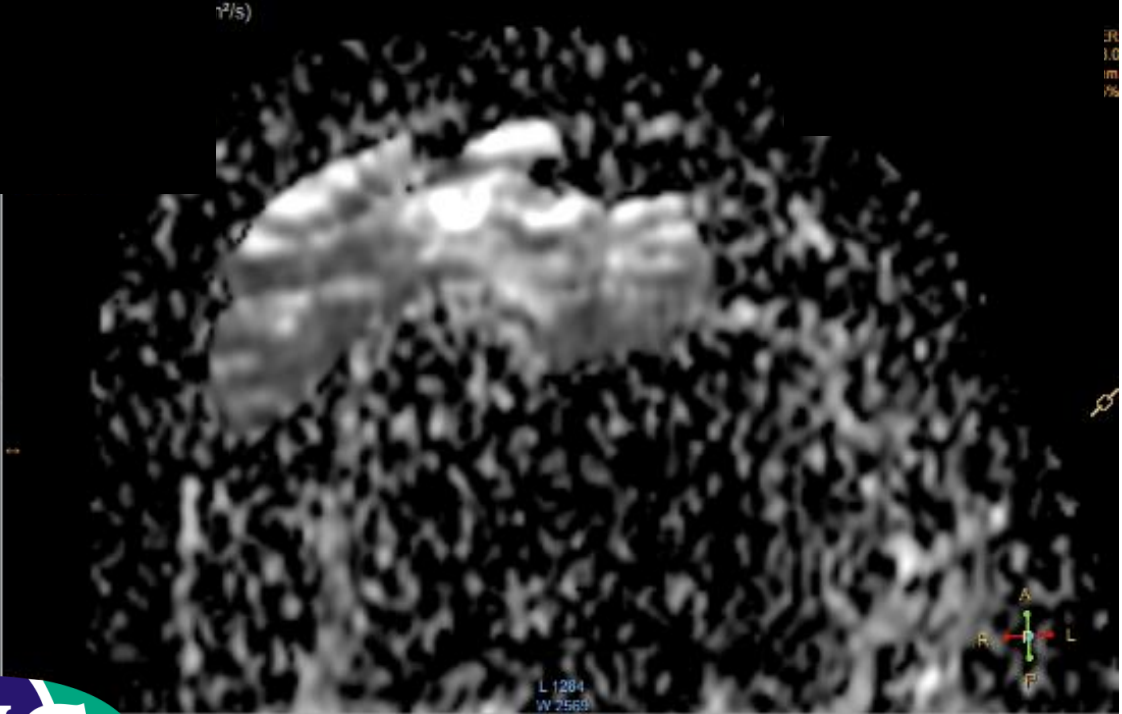
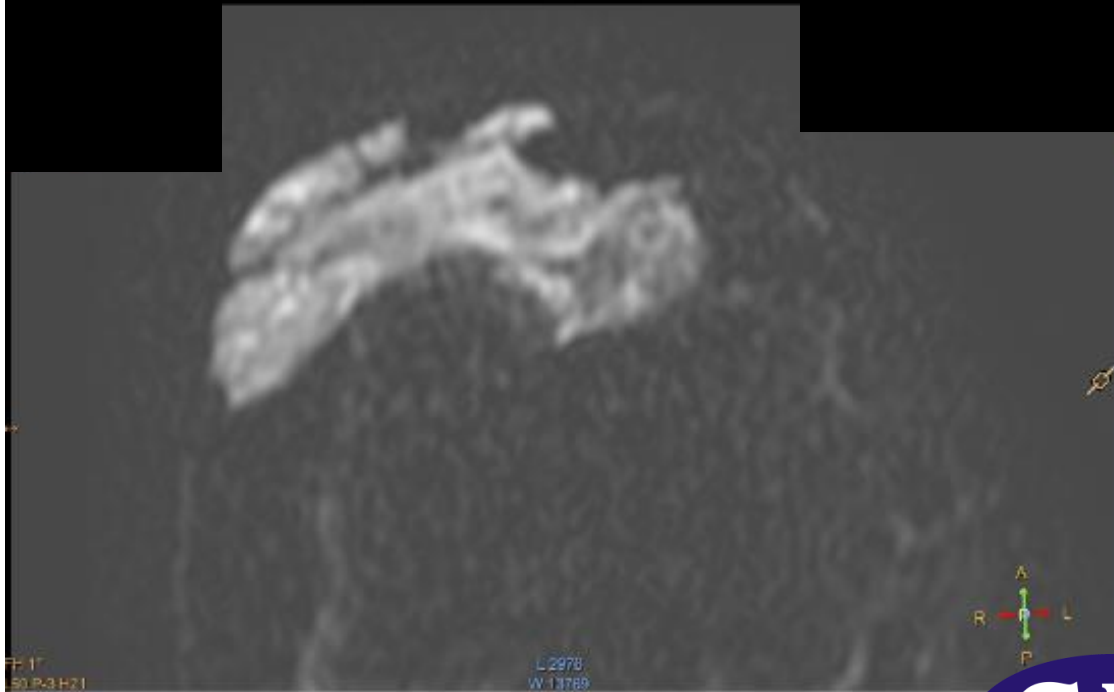


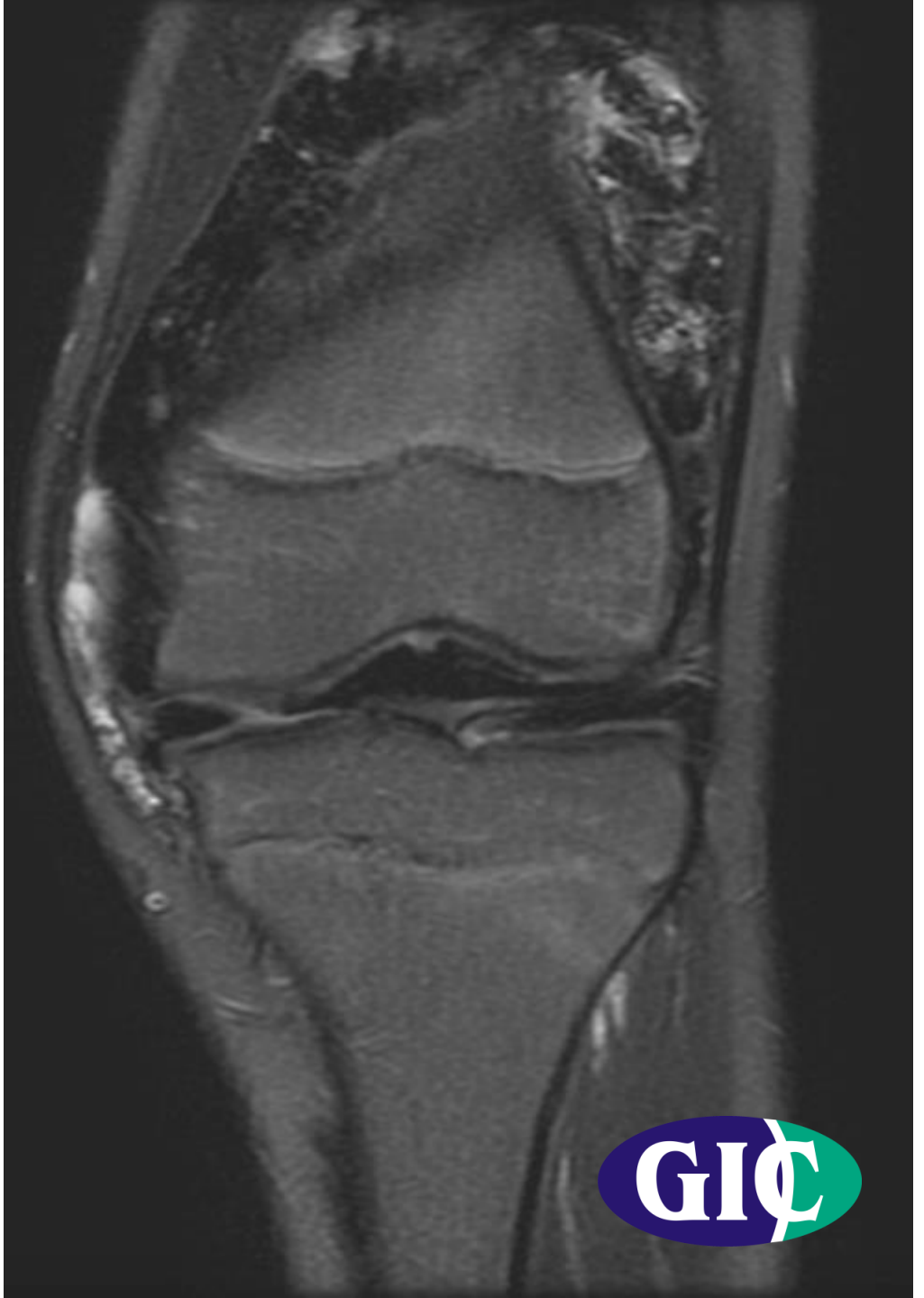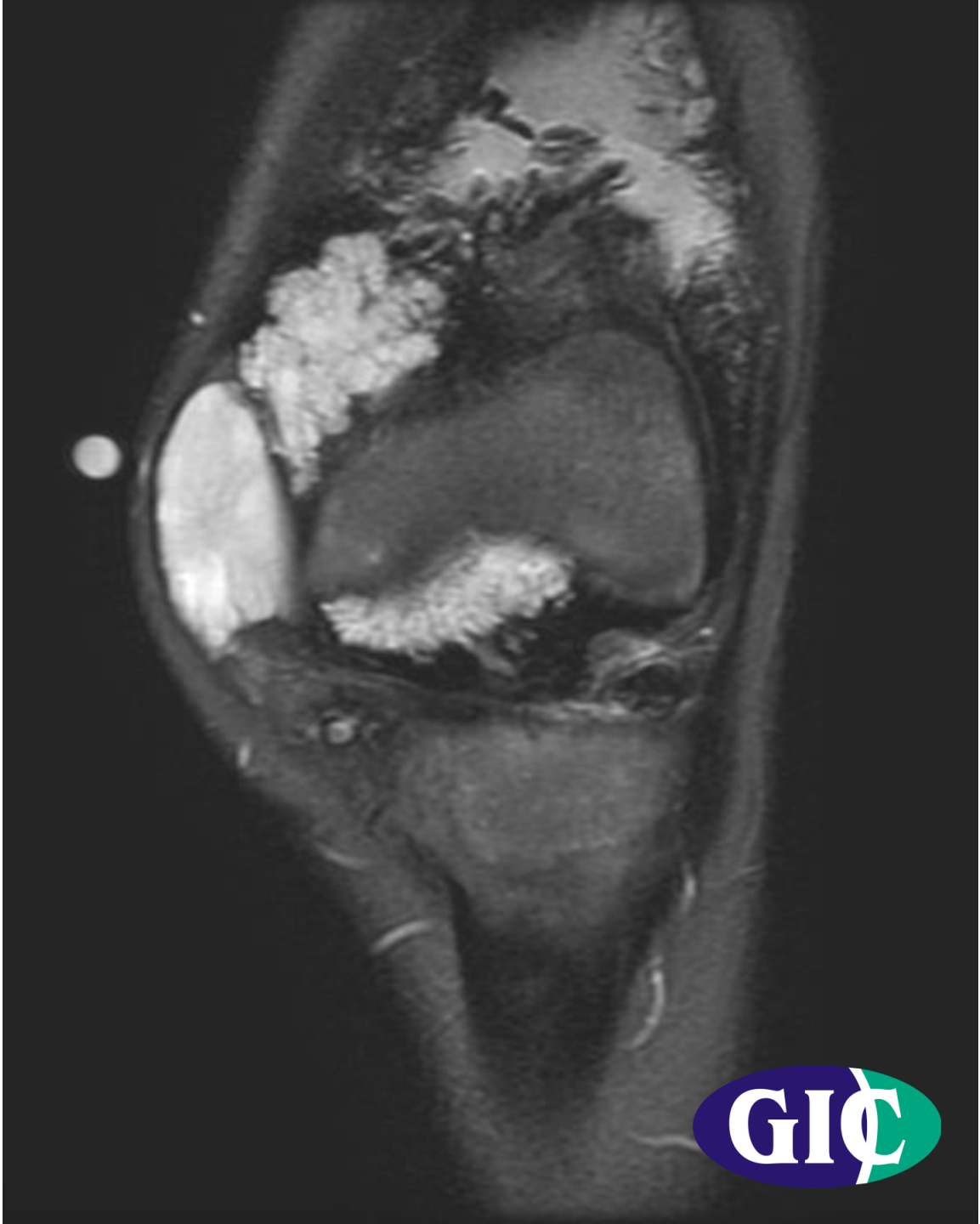
GIC













# Diagnosis

Ganglion / Synovial cyst with Hemorrhage