


MICOD 16/09/2023  
Contributor: Dr. D. K. Singh

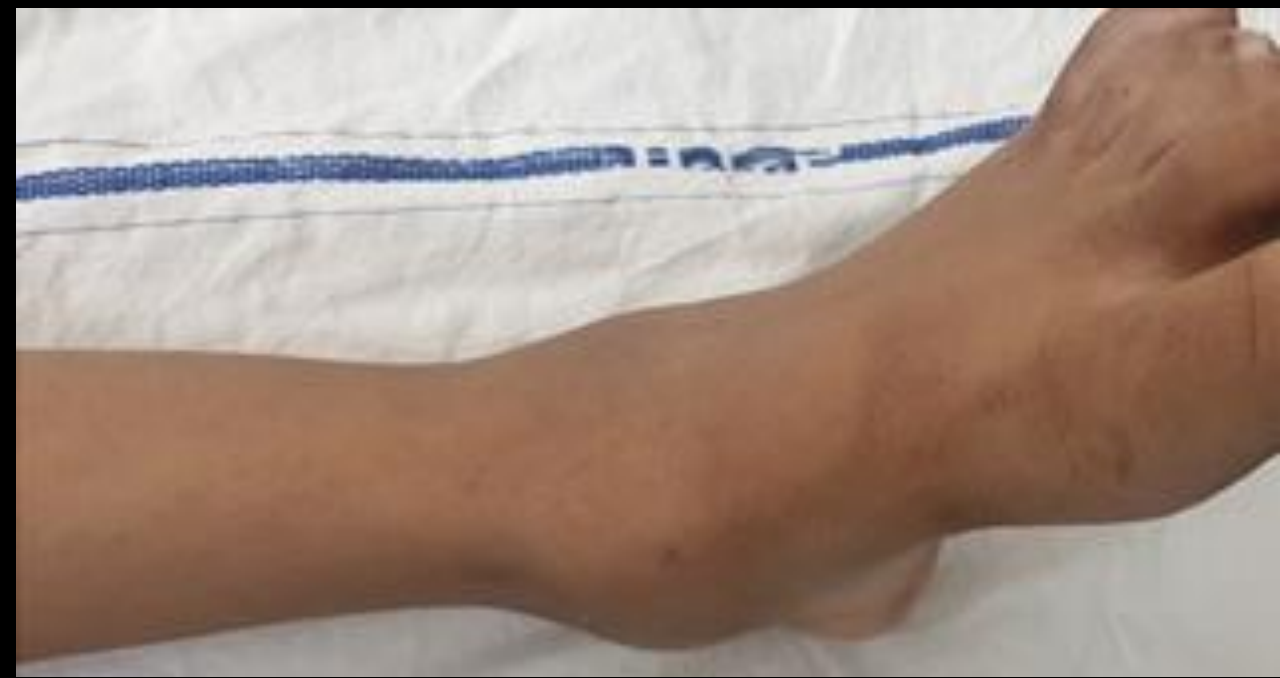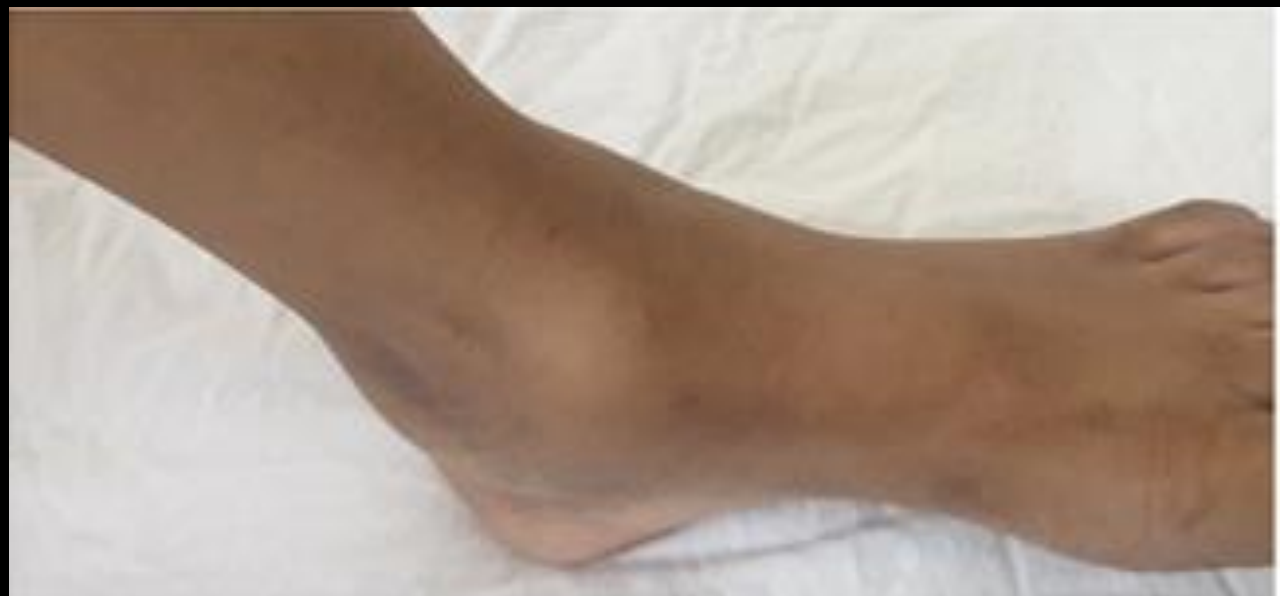# MI-COD

MSS INDIA- Case Of the Day

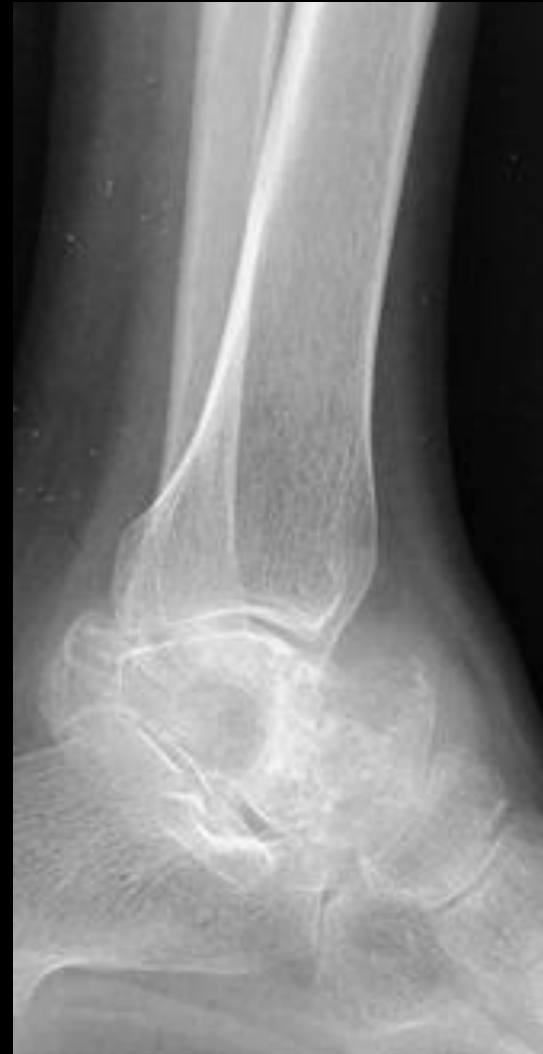
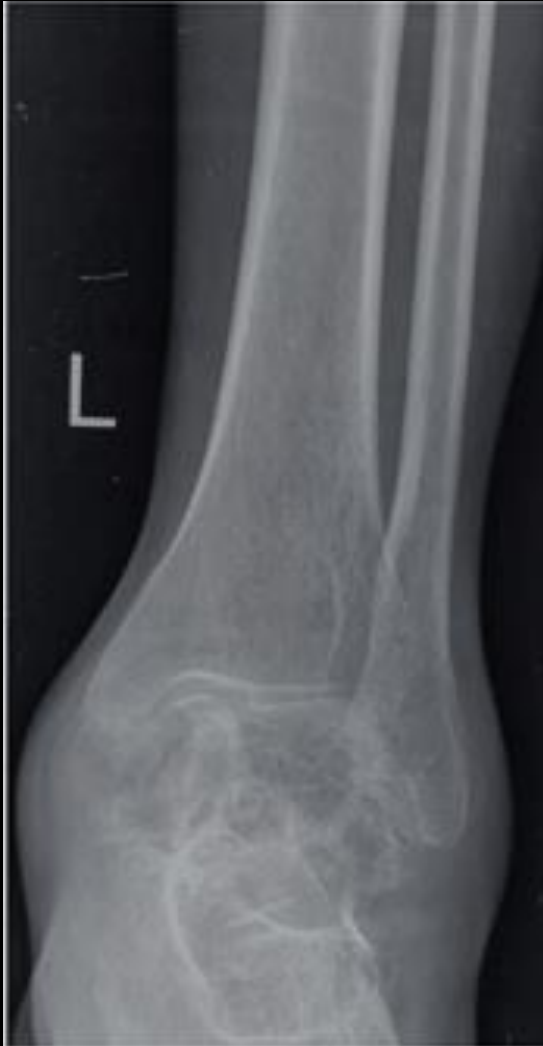
**14 year young female with pain and swelling in ankle since 18 months**

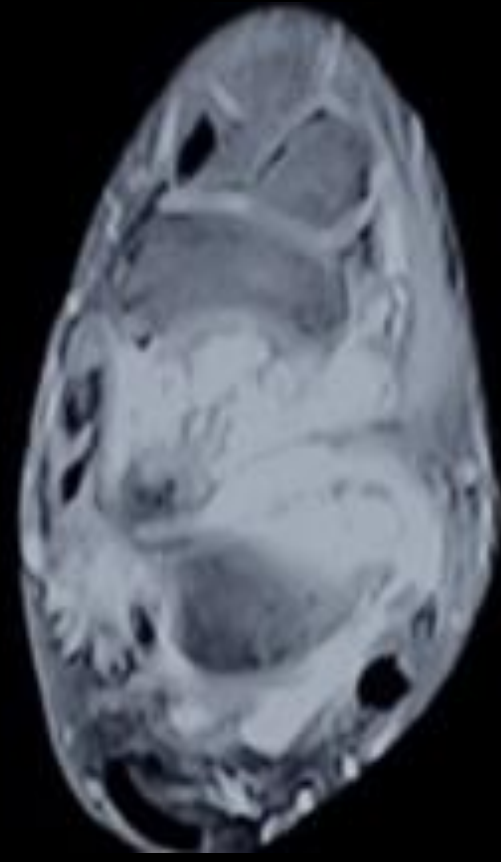
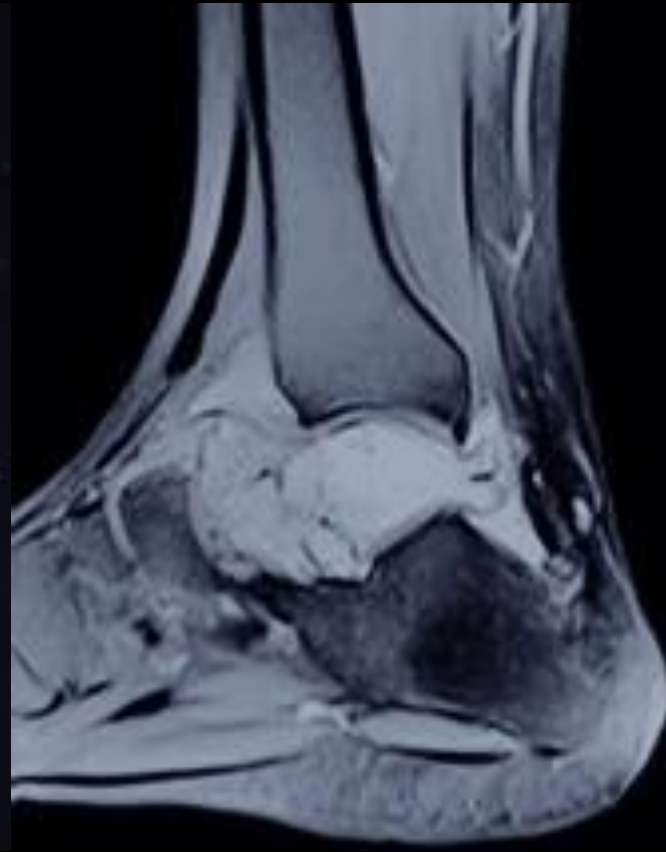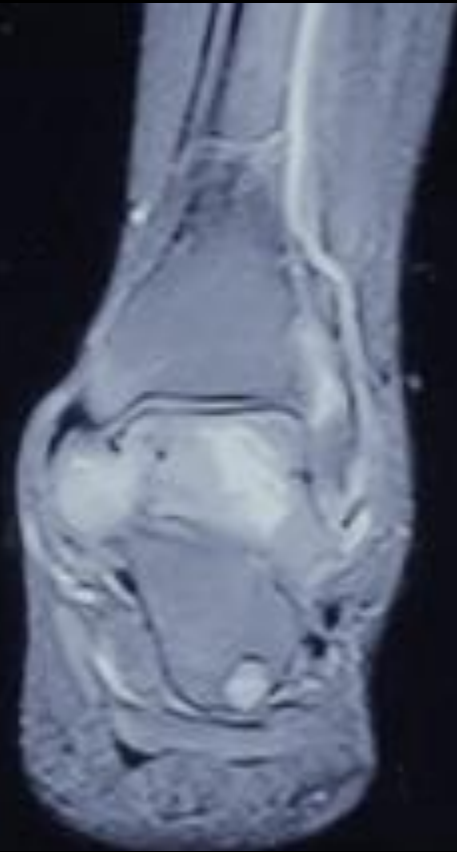
# Clinical Photograph

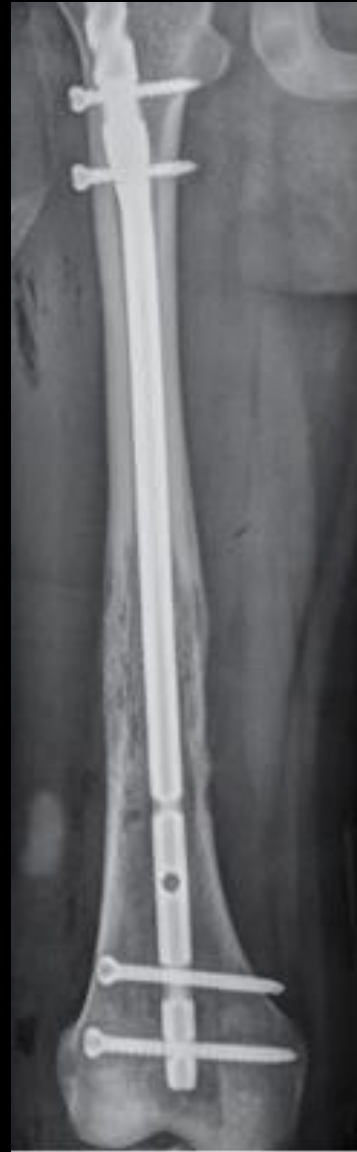
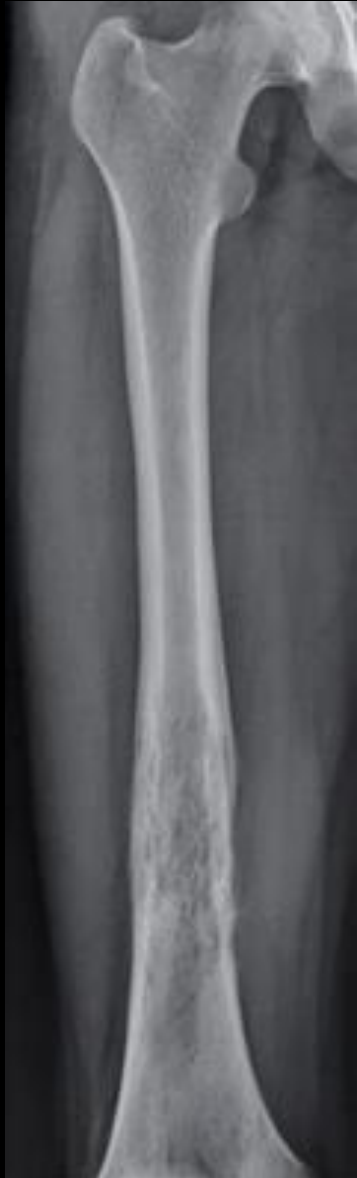
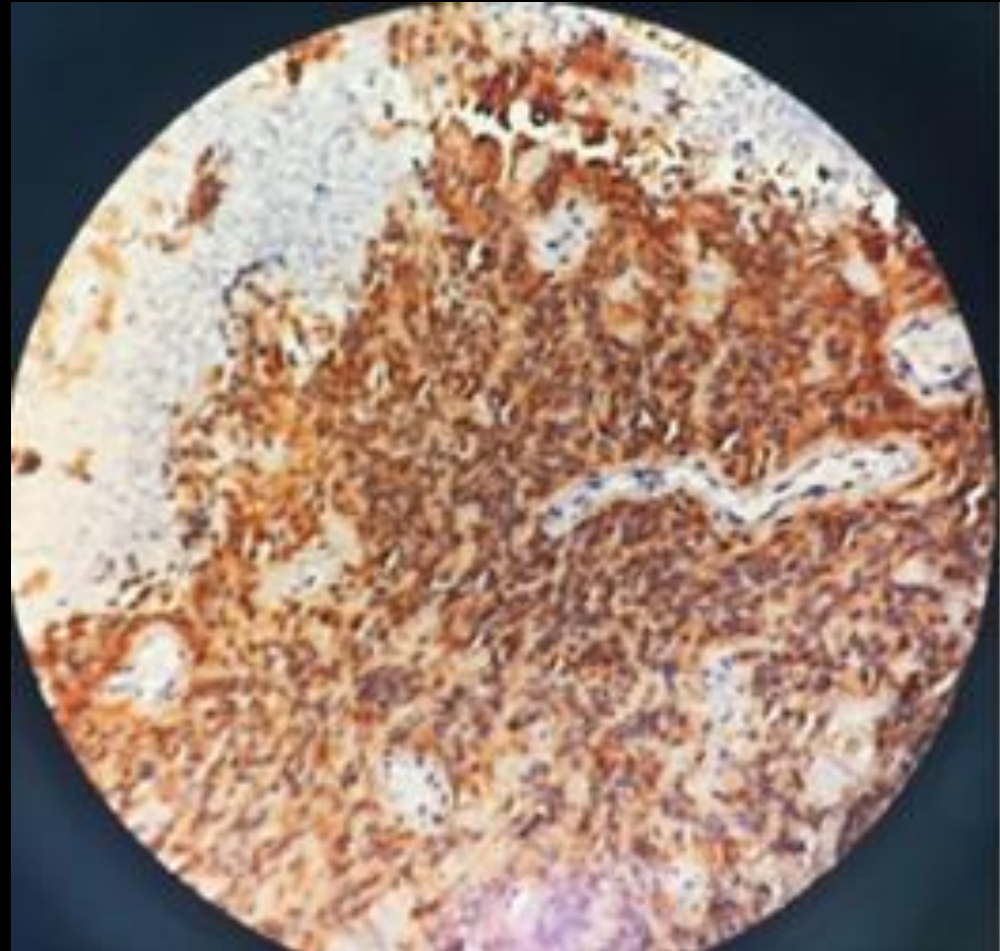
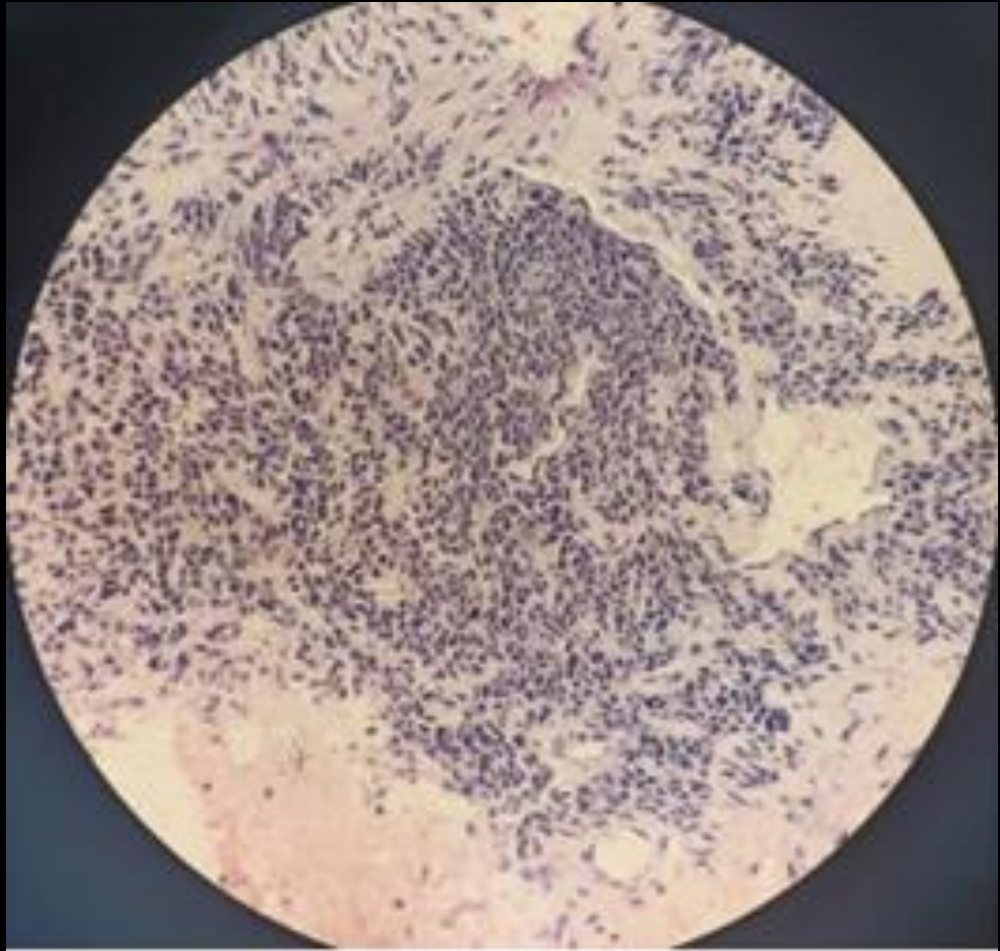
# Plain Radiograph



# MRI







# Diagnosis

Ewings sarcoma of talus with bone to bone mets.



Review began 08/29/2022  
Review ended 10/22/2022  
Published 10/31/2022

© Copyright 2022

Jalan et al. This is an open access article distributed under the terms of the Creative Commons Attribution License CC-BY 4.0., which permits unrestricted use, distribution, and reproduction in any medium, provided the original author and source are credited.

# Ewing's Sarcoma of the Talus in an Adolescent Female: An Unusual Case Presentation With Review of Literature

Divesh Jalan<sup>1</sup>, Ravi Sreenivasan<sup>1</sup>, Rohit Prasad<sup>1</sup>, Dharmendra K. Singh<sup>2</sup>, Amit K. Jha<sup>1</sup>

1. Orthopaedics, Vardhman Mahavir Medical College and Safdarjung Hospital, New Delhi, IND 2. Radiology, Vardhman Mahavir Medical College and Safdarjung Hospital, New Delhi, IND

**Corresponding author:** Rohit Prasad, rhan87@gmail.com

---

---

## Abstract

Ewing's sarcoma is an aggressive primary malignant bone tumor that affects long and flat bones and is commonly seen in children and adolescents. The involvement of the foot especially the talus is an extremely rare entity with less than 15 cases reported in the literature. The rarity and atypical symptoms often lead to delays in diagnosis affecting the prognosis and survival. We present a 14-year-old female with pain and swelling of the left ankle for 18 months. She was being treated previously for an ankle sprain and was later suspected of avascular necrosis of the talus, before presenting to us. Clinicoradiology-pathological workup confirmed the diagnosis of Ewing sarcoma of the talus. Further, the metastatic workup revealed multiple skeletal metastases at the time of diagnosis. The metastatic lesion of the right femur required prophylactic fixation, otherwise, the patient was treated with palliative chemotherapy and radiotherapy. Ewing's sarcoma of the foot involving the talus is extremely rare and is a commonly misdiagnosed entity, affecting the overall prognosis of the patient. A high index of suspicion and a multidisciplinary approach is imperative for its early diagnosis and definitive management.

---