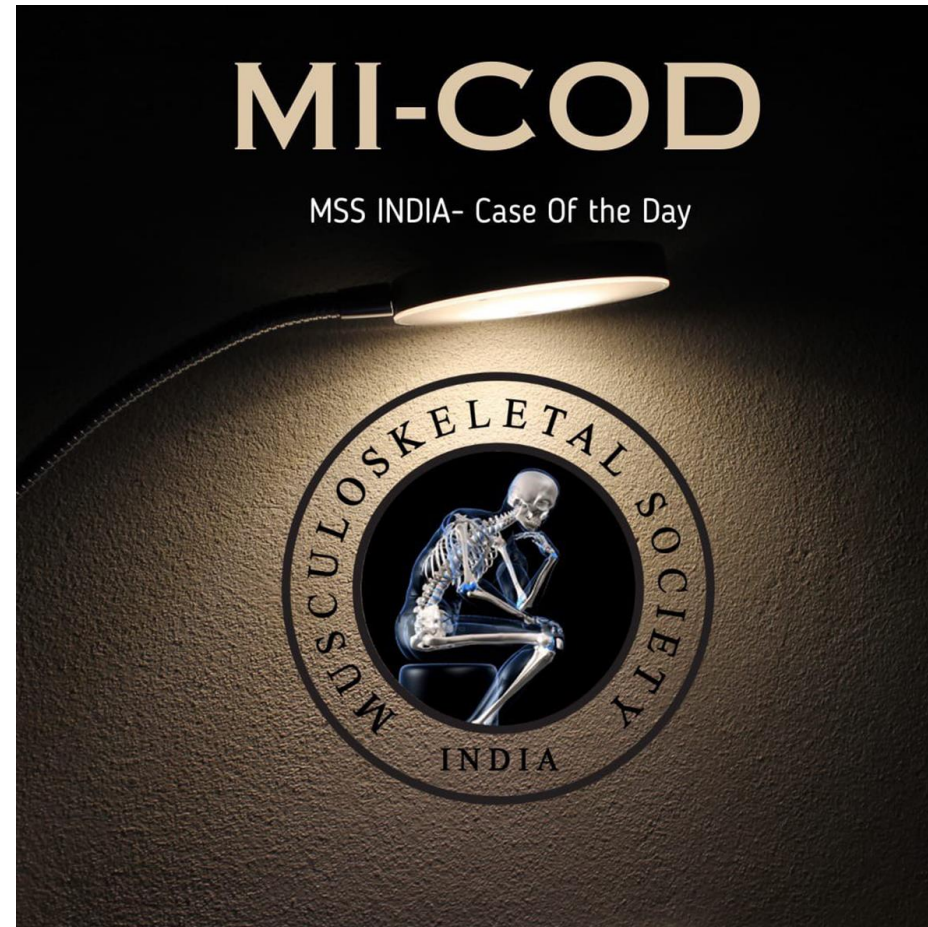


MICOD -10/09/2023

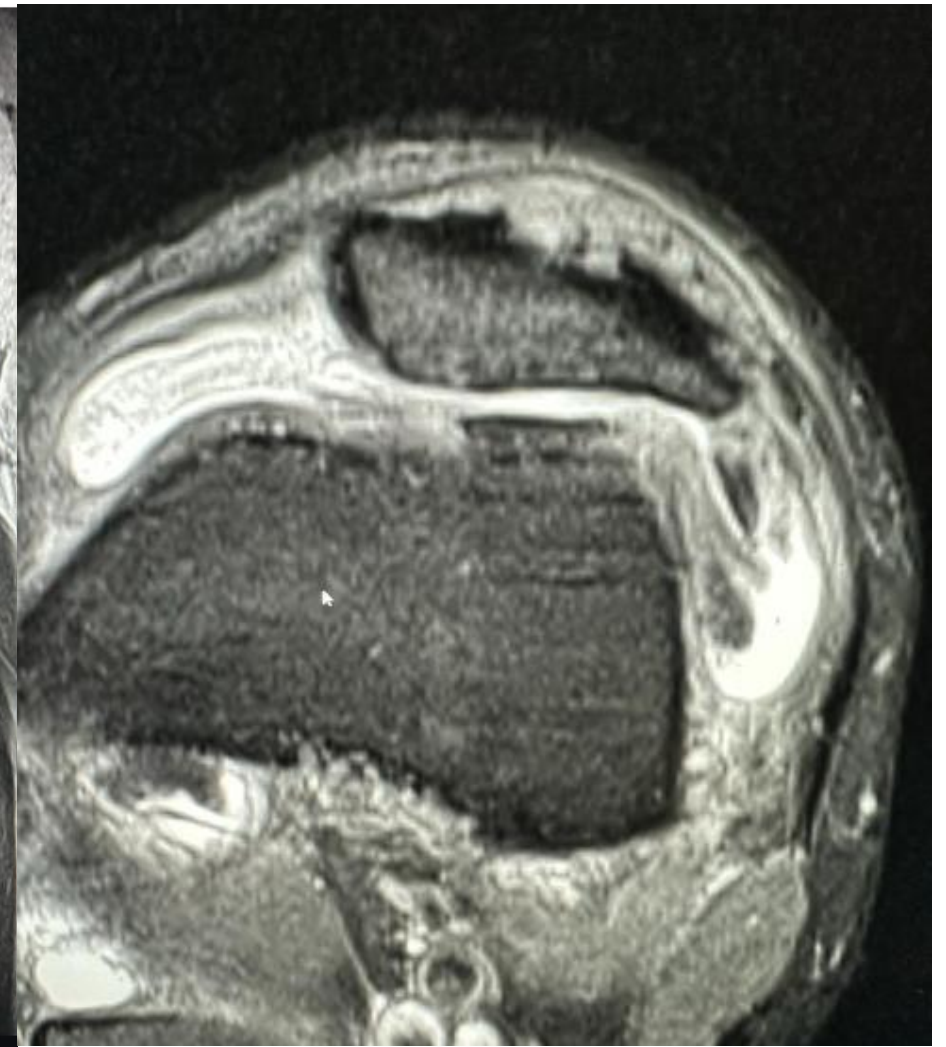
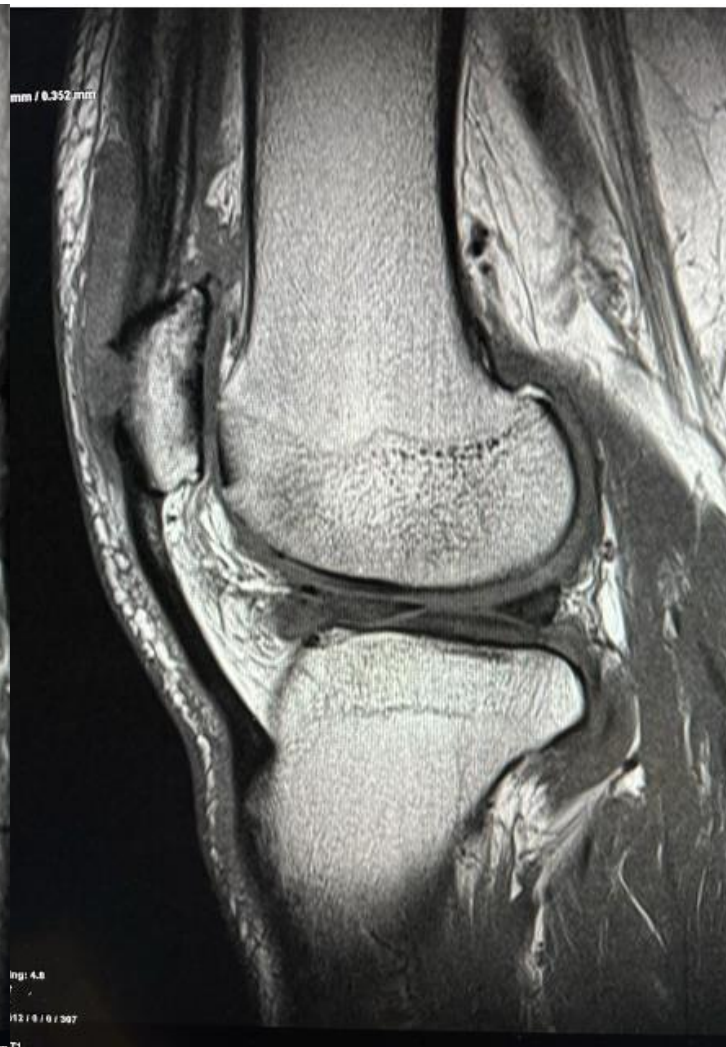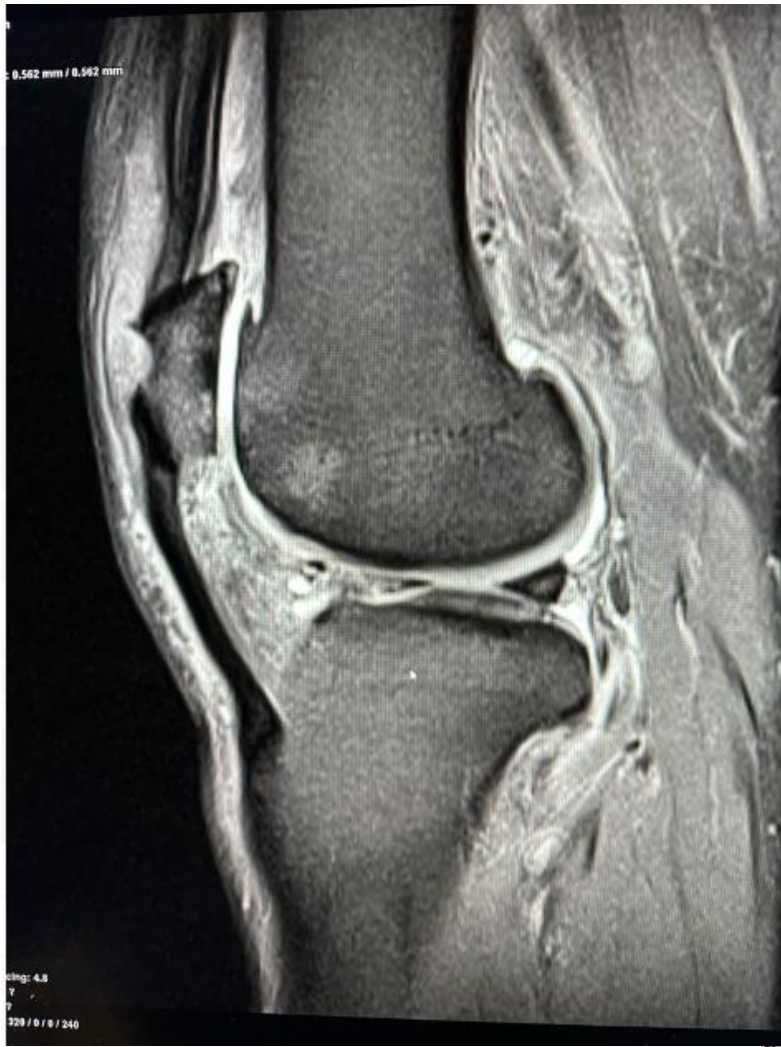Case contributor –Dr. Hema Nalini Choudur

Professor, Musculoskeletal Radiology, Head: Division of Musculoskeletal Imaging, McMaster University



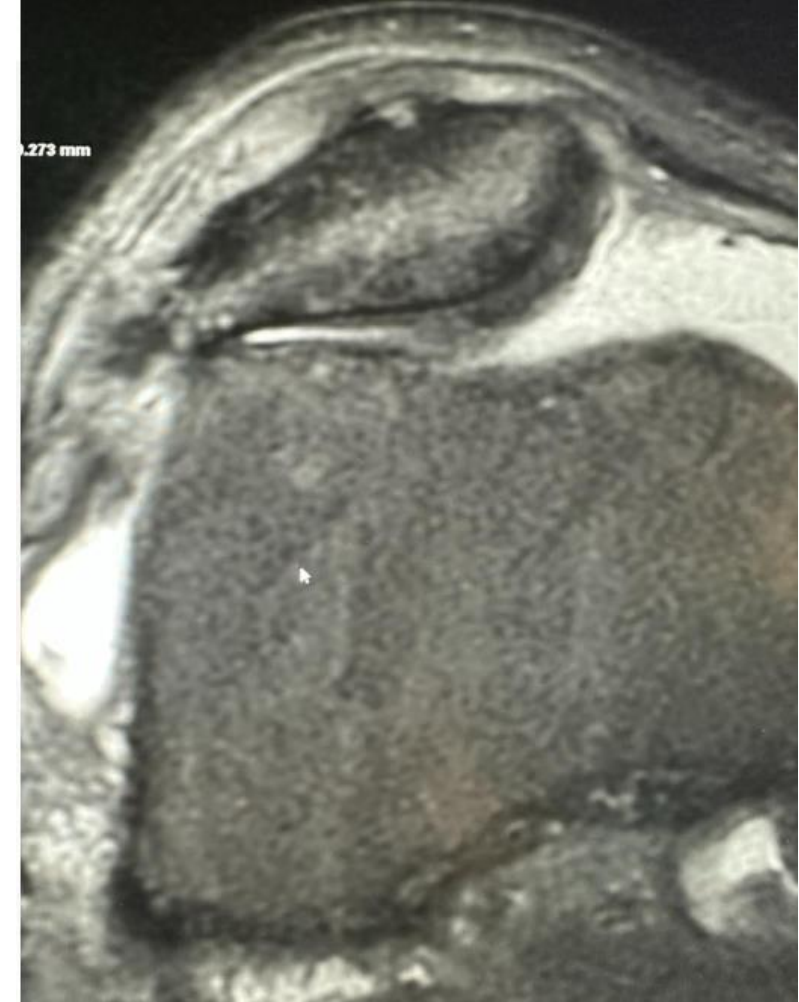
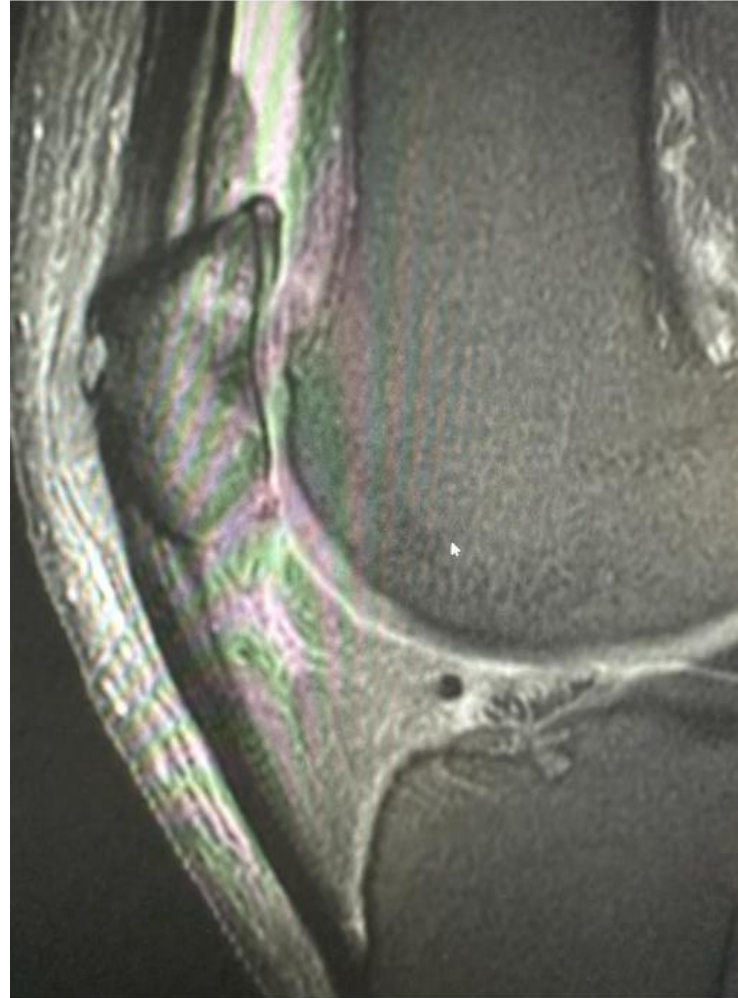
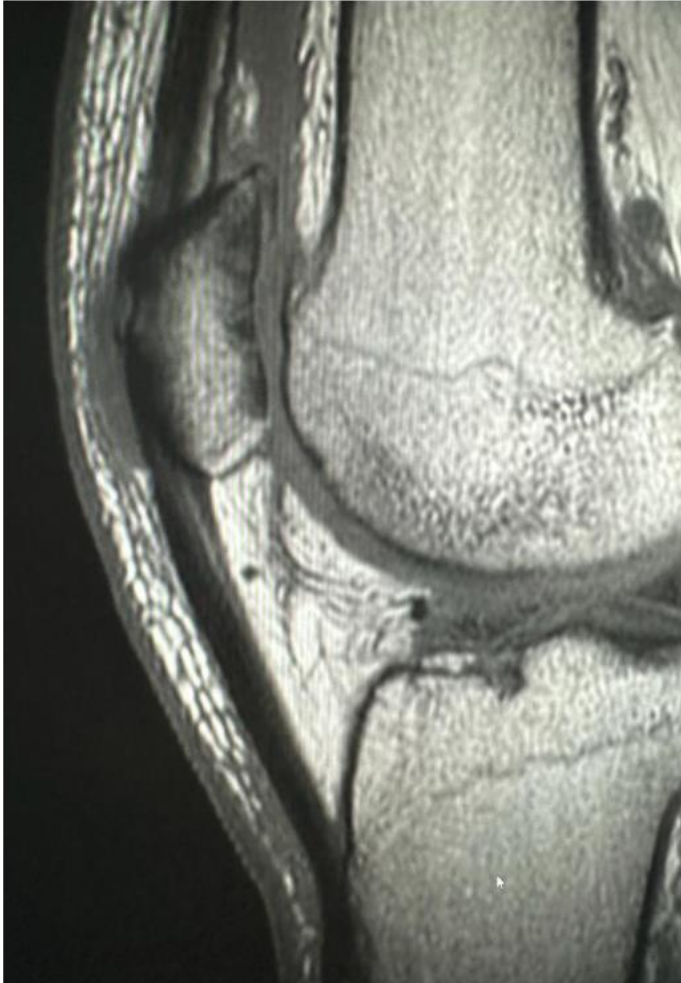- 60 year old male, long standing knee instability.

Right knee MRI – done Sept 2023



Discuss diagnosis/differentials.

Left knee mri - 2018



Pre-patellar bursitis.

- Normal uric acid levels.
- No h/ trauma or inflammatory arthropathy. On questioning, patient is a brick layer by occupation.

Chronic defects in anterior patella are bilaterally symmetrical. They are from chronic pressure changes/ traction of quadriceps from brick laying. Associated chronic prepatellar bursitis.