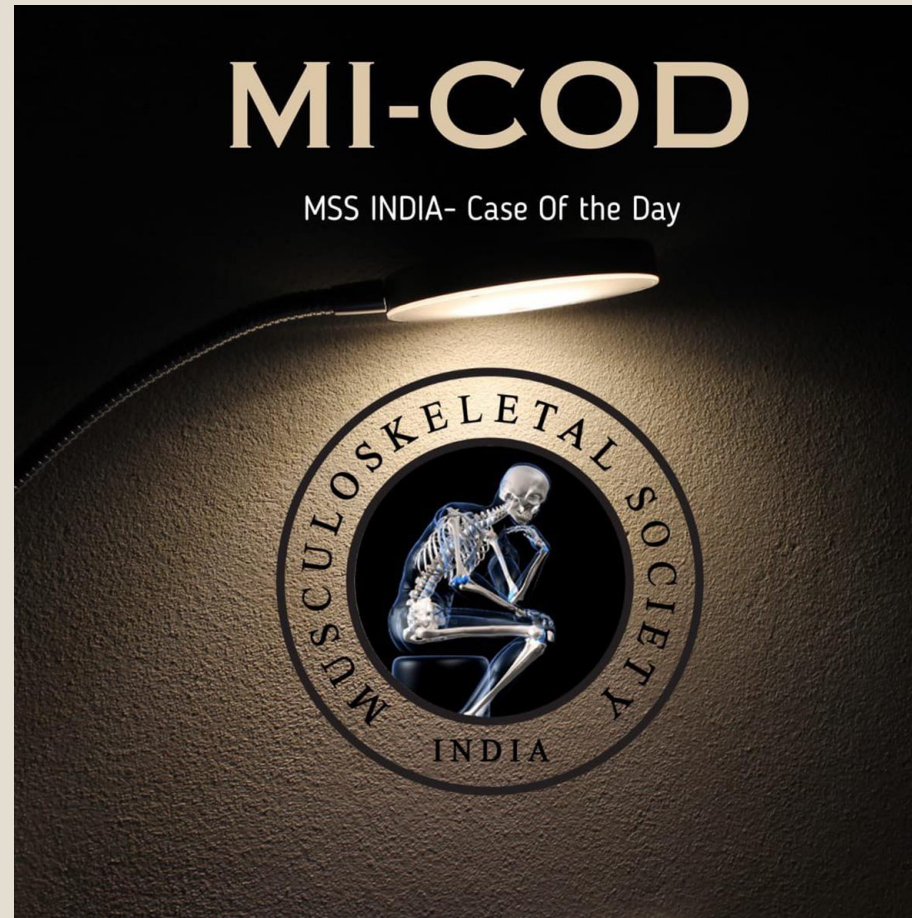
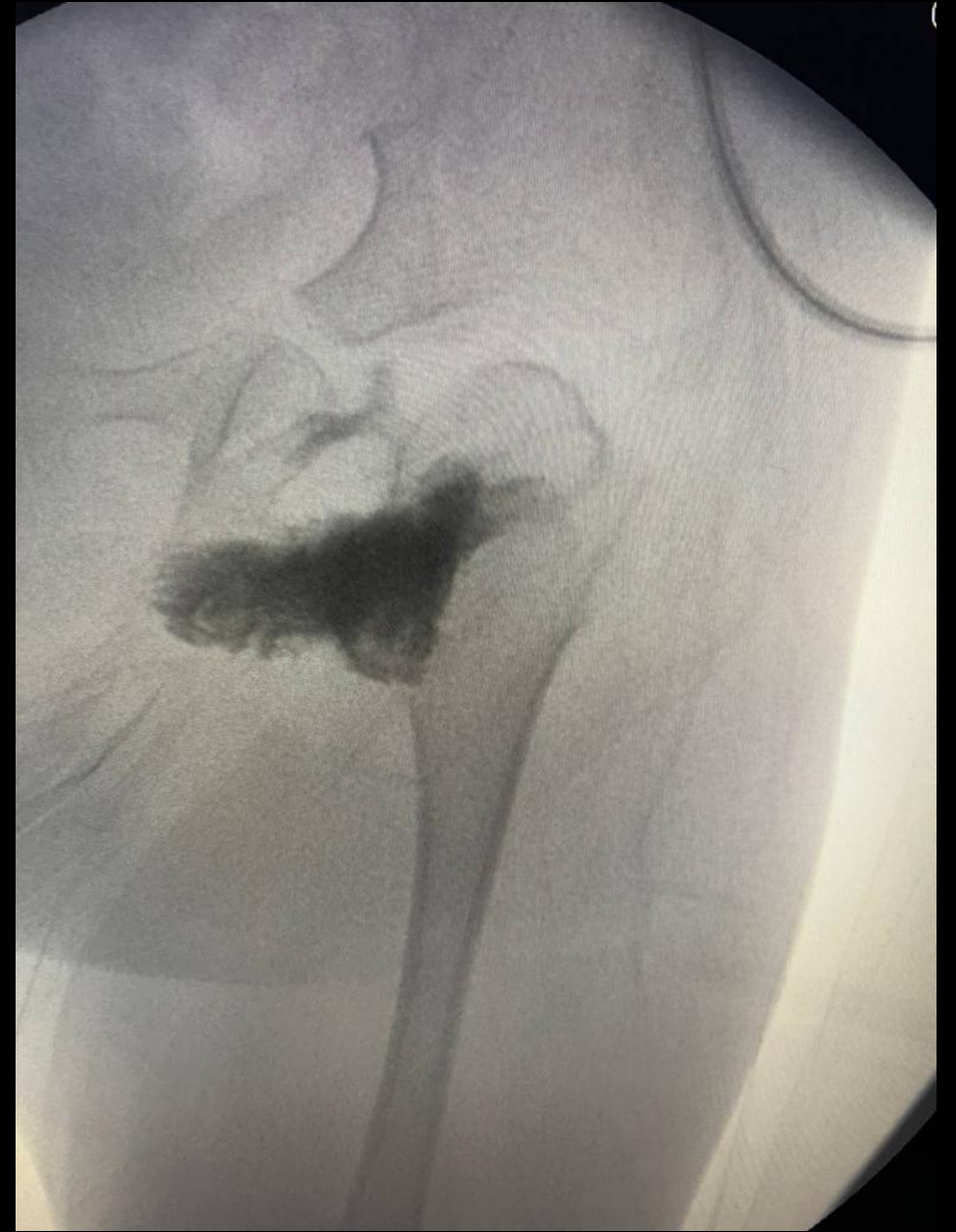
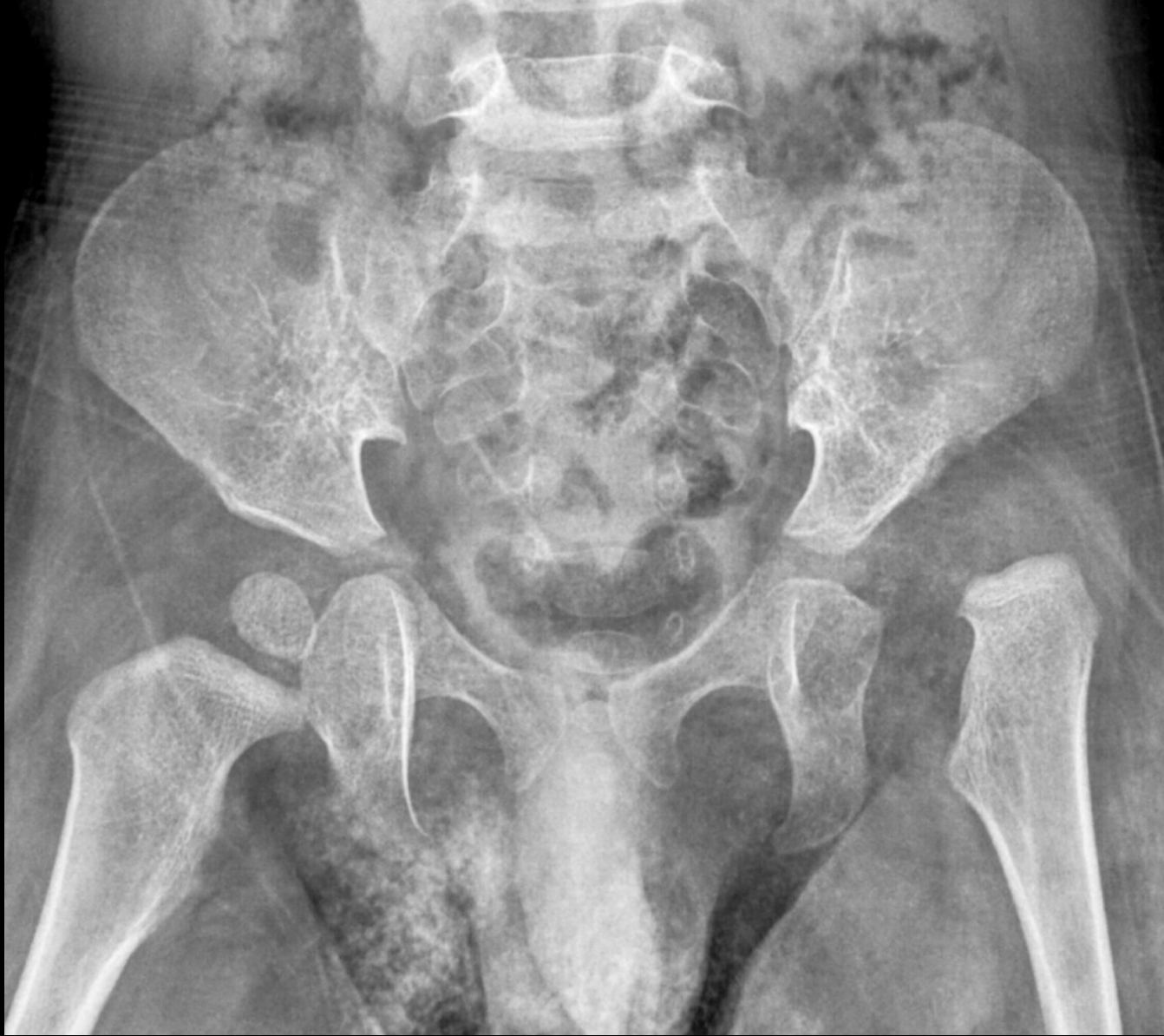
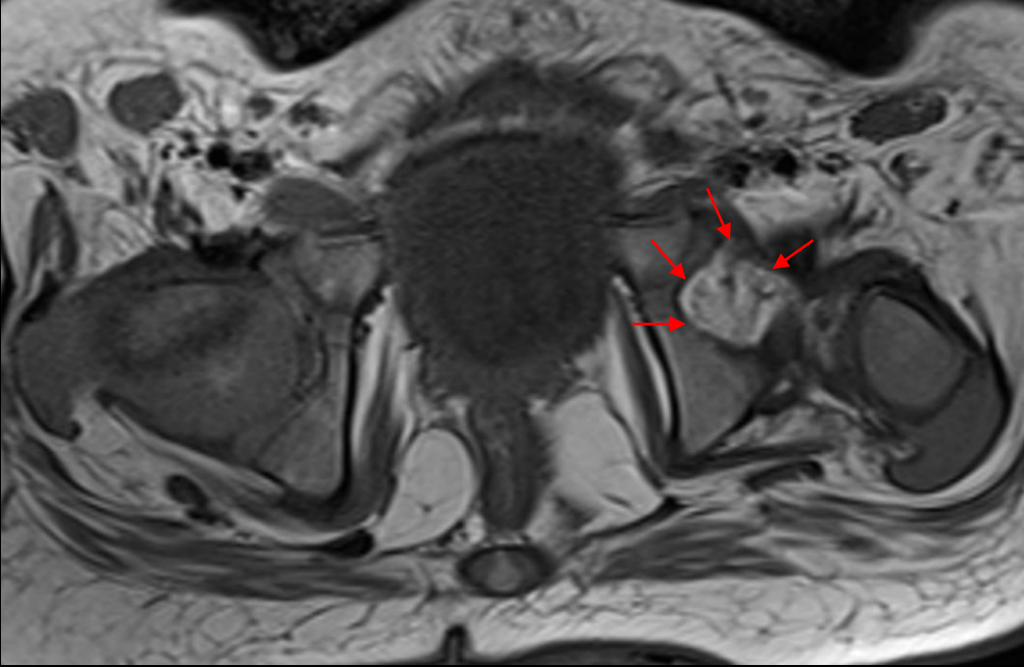
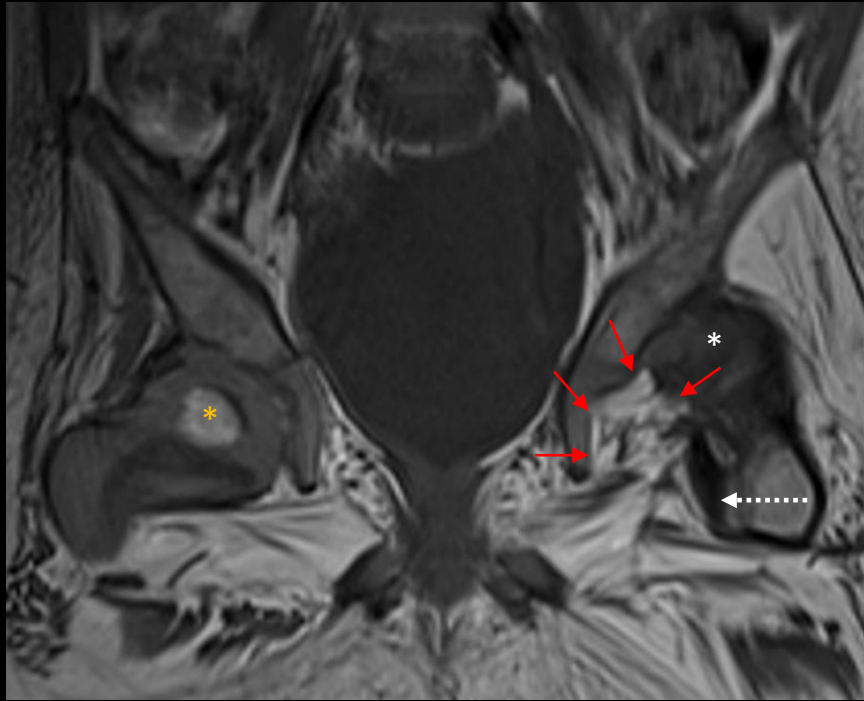
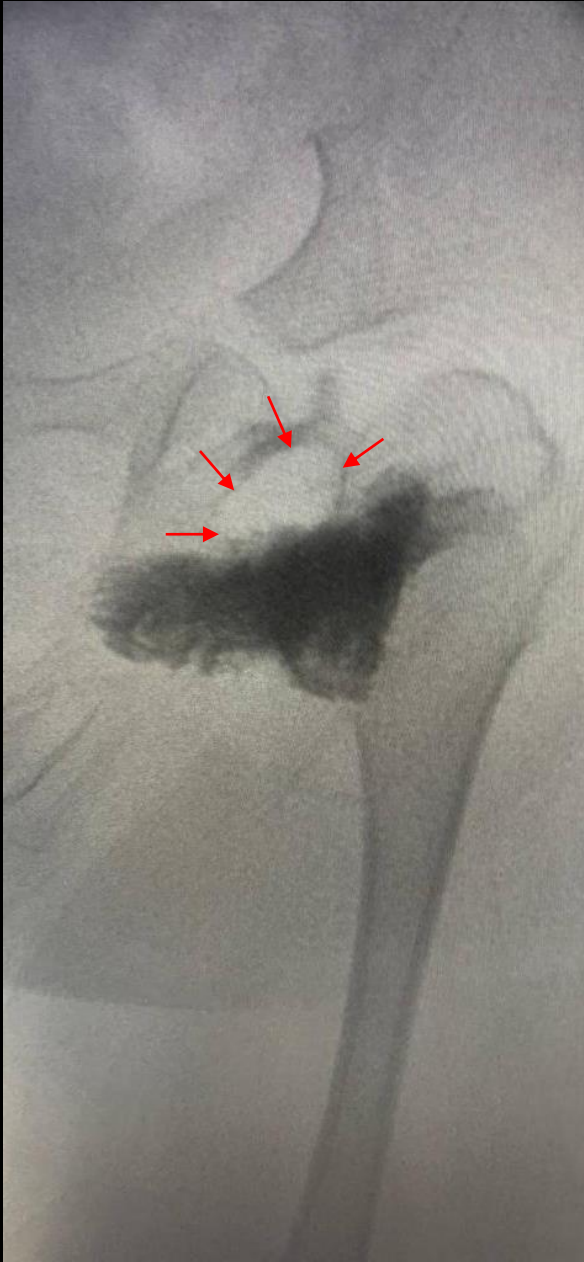MICOD -06/09/2023

Case contributor – Dr. Darshana Sanghvi



Question: In this case of left hip DDH seen on radiograph, surgeon was unable to perform a closed reduction. What feature seen on the arthrogram might have hindered reduction?





Answer: Thickened pulvinar fat pad (red arrows). The fat pad is best displayed on T1 WI. The fat pad may be resected if open reduction is performed when conservative Rx fails. T1WI also shows normal ossified right femoral head (*) & abnormal unossified left femoral head (*) outside the dysplastic vertically oriented shallow left acetabulum. Another structure that may hinder reduction is an interposed thickened iliopsoas tendon (dotted white arrow).