

MICOD -01/09/2023

Case contributor – Dr.Raj Chari

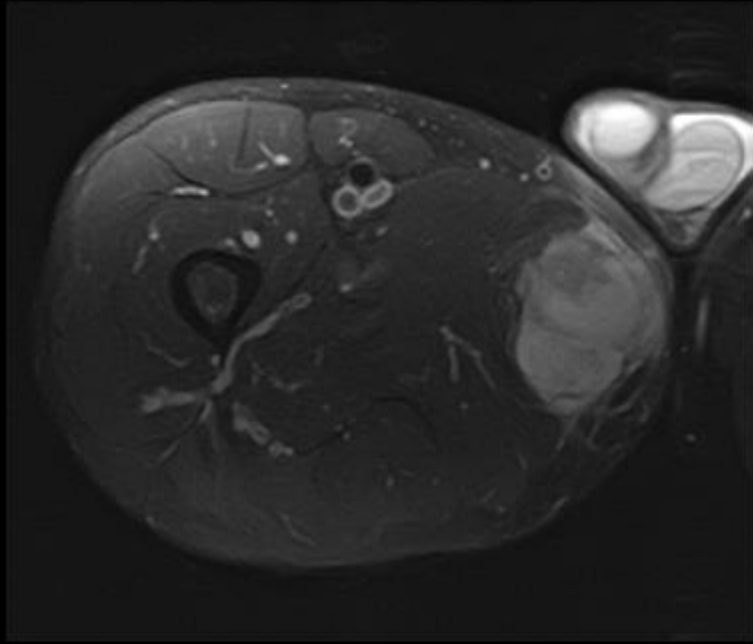
MI-COD

MSS INDIA- Case Of the Day

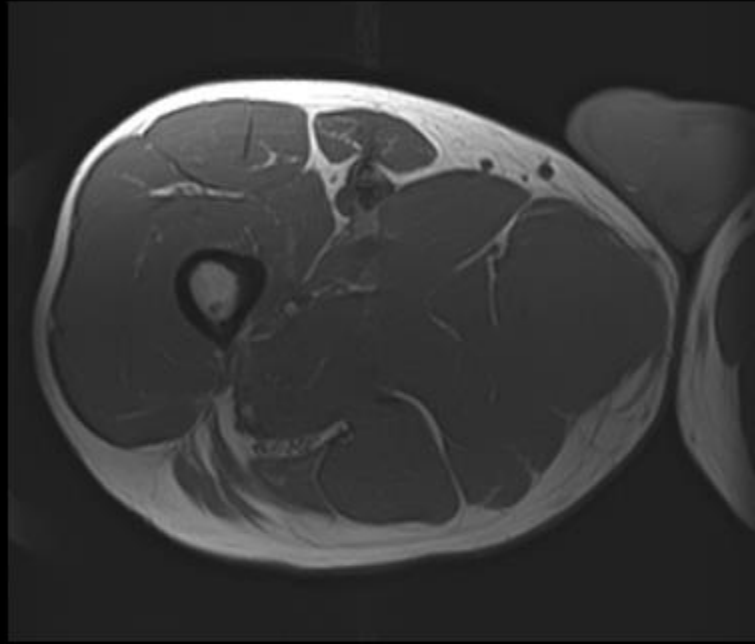


Clinical details

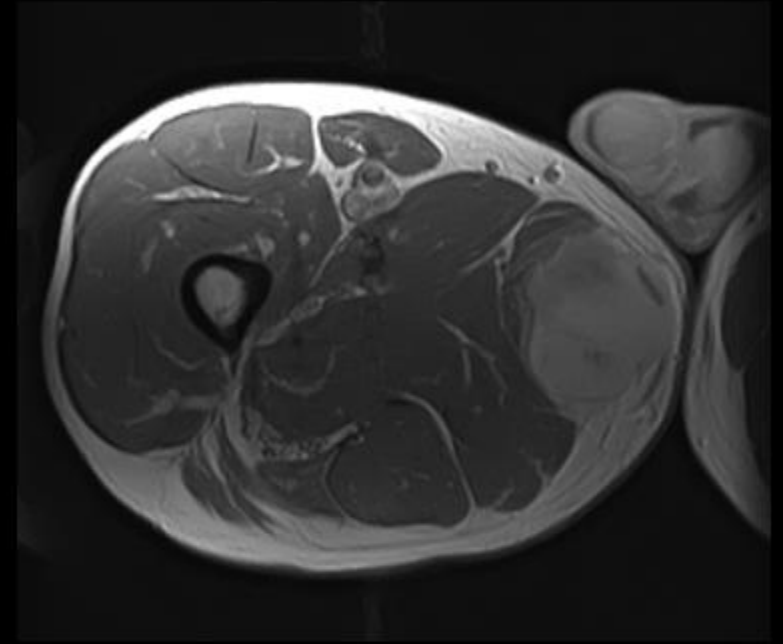
- 40 year old gentleman
- Right medial thigh swelling
- Underwent appropriate investigations



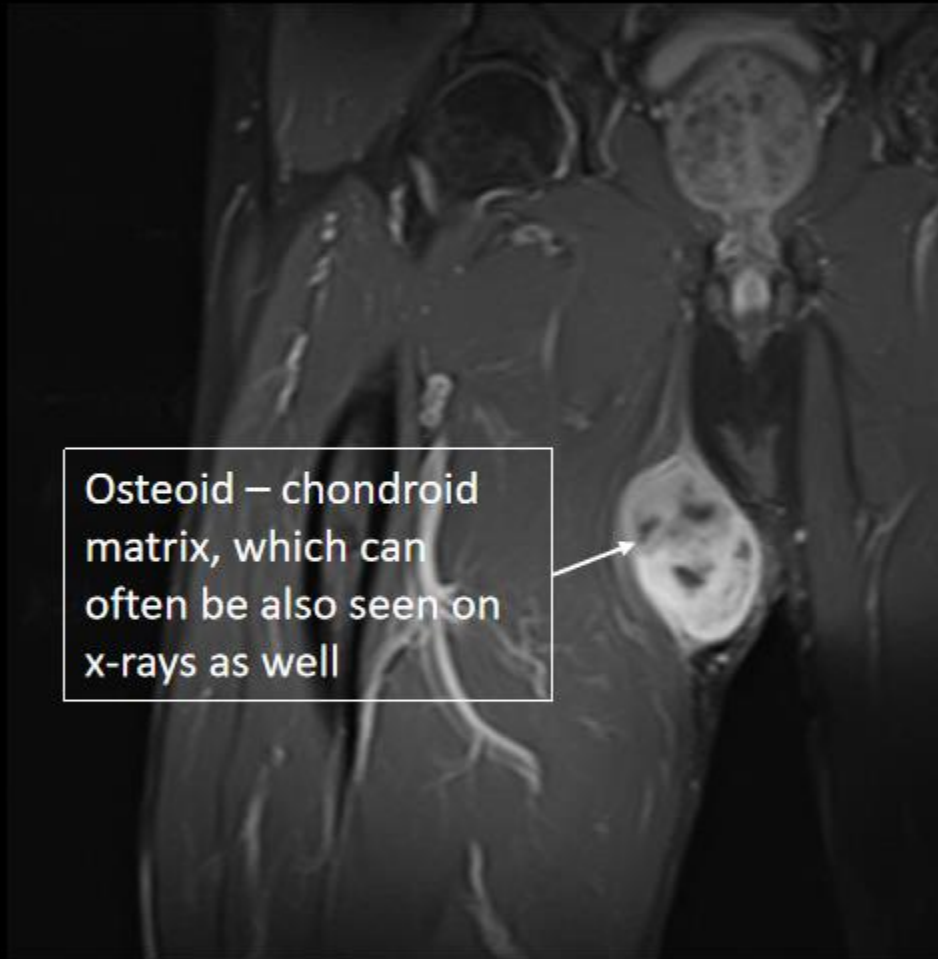T2FS



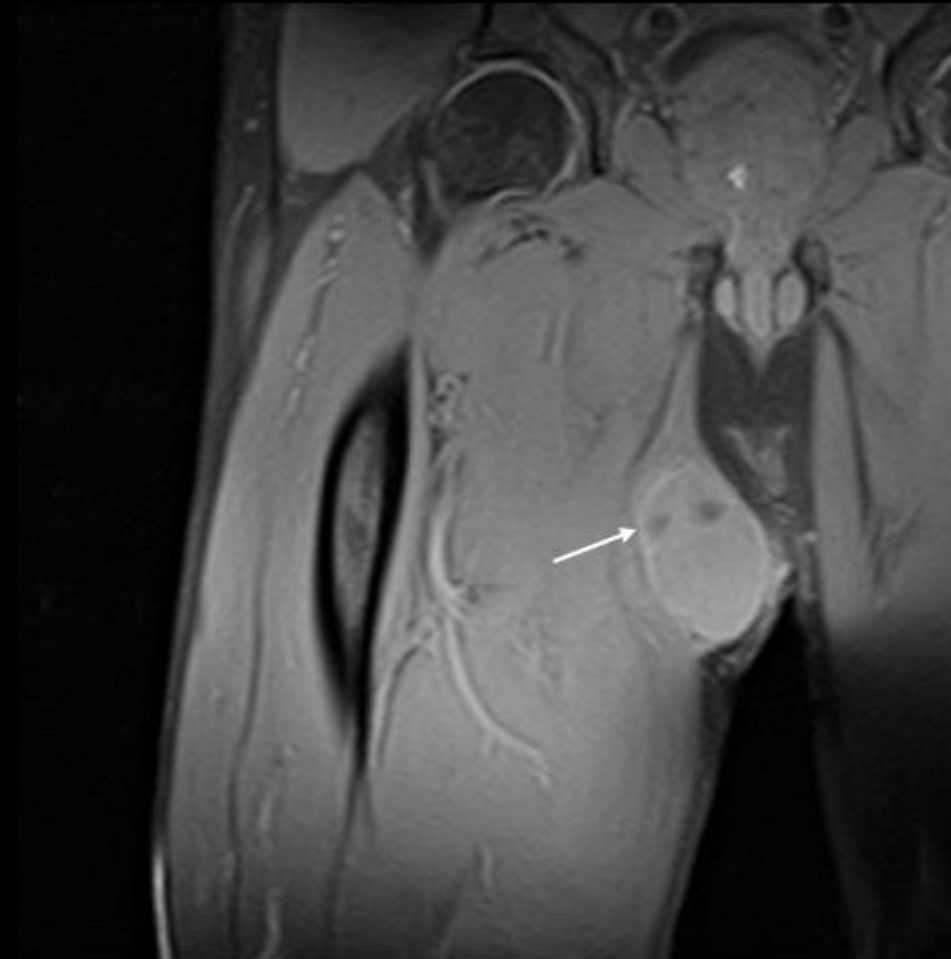
T1



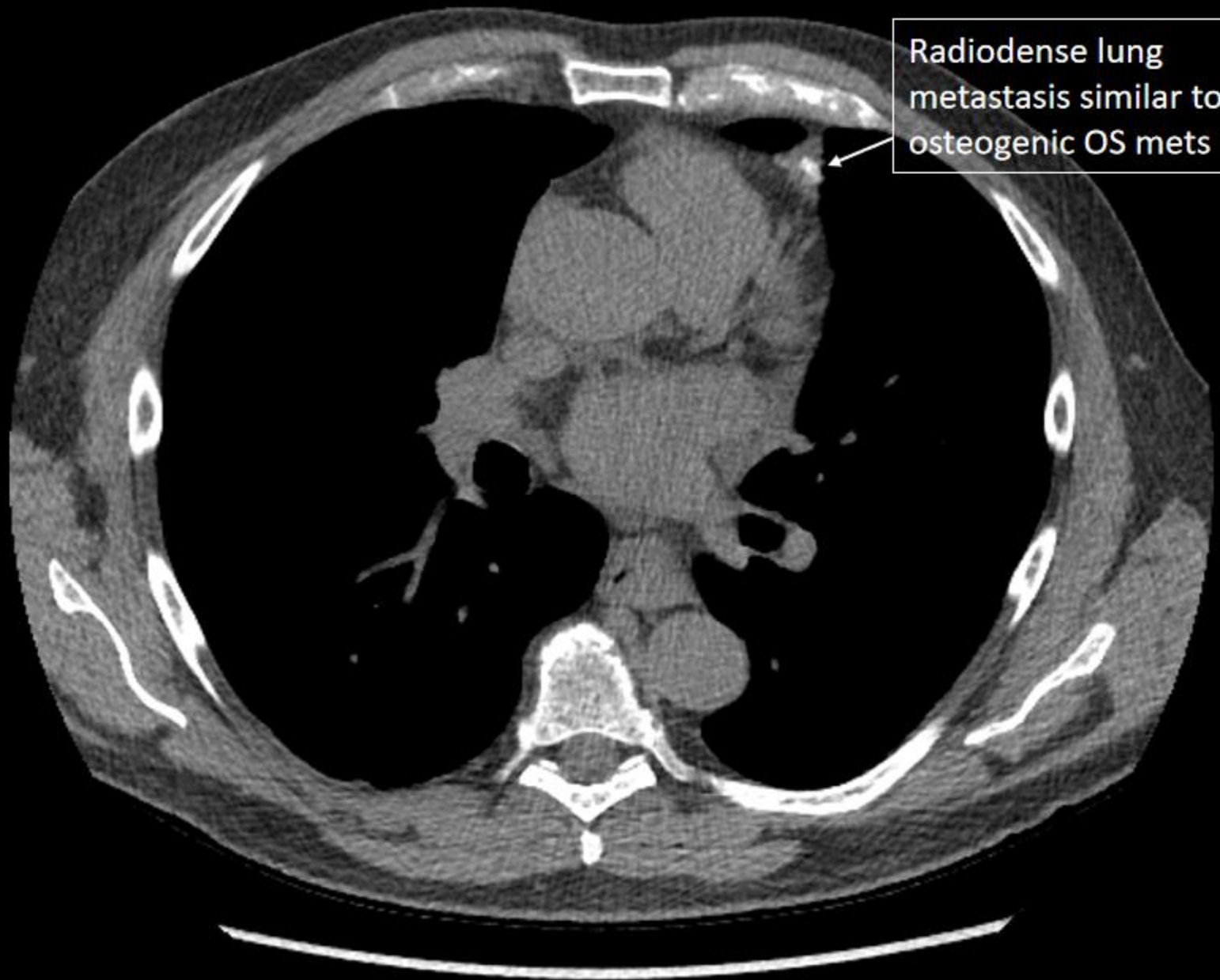
T1 post contrast



T2FS



T1 post contrast



Radiodense lung metastasis similar to osteogenic OS mets

Diagnosis: Extra-skeletal Osteosarcoma

Extraskeletal osteosarcoma:

- Rare malignant mesenchymal soft-tissue neoplasm without attachment to the skeleton, which is able to produce osteoid or cartilaginous matrix.
- Extraskeletal osteosarcoma accounts for approximately 1% of all soft-tissue sarcomas and 4% of osteosarcomas.
- Osteogenic osteosarcoma is the most common primary malignancy of bone, and extraskeletal osteosarcoma is histologically indistinguishable from it.
- Although extraskeletal osteosarcoma may also contain some fibroblastic components, by definition, no other differentiation may be present.
- Extraskeletal osteosarcoma was first described by Wilson in 1941, but it was Fine and Stout in 1956 who suggested that it may show behavior similar to primary osteogenic osteosarcoma in bone.
- Subsequent studies have indicated that extraskeletal osteosarcoma should be considered clinically and therapeutically separate from osteogenic osteosarcoma.

Management:

- Tissue diagnosis
- Staging
- Wide local excision
- Lung met resection
- Chemotherapy